

Smith & Tanagho's General Urology, 18e >

## Chapter 17. Urinary Stone Disease

### Urinary Stone Disease: Introduction

Urinary calculi are the third most common affliction of the urinary tract, exceeded only by urinary tract infections and pathologic conditions of the prostate. They are common in both animals and humans. The nomenclature associated with urinary stone disease arises from a variety of disciplines. Struvite stones, for example, composed of magnesium ammonium phosphate hexahydrate, are named in honor of H.C.G. von Struve (1772–1851), a Russian naturalist. Before the time of von Struve, the stones were referred to as guanite, because magnesium ammonium phosphate is prominent in bat droppings. Calcium oxalate dihydrate is frequently referred to as weddellite, because it was commonly found in floor samples collected from the Weddell Sea in Antarctica. The history of the nomenclature associated with urinary stone disease is as intriguing as that of the development of the interventional techniques used in their treatment.

Urinary stones have plagued humans since the earliest records of civilization. The etiology of stones remains speculative. If urinary constituents are similar from each kidney and if there is no evidence of obstruction, why do most stones present in a unilateral fashion? Why do not small stones pass uneventfully down the ureter early in their development? Why do some people form one large stone and others form multiple small calculi? There is much speculation concerning these and other questions.

Advances in the surgical treatment of urinary stones have outpaced our understanding of their etiology. As clinicians, we are concerned with an expedient diagnosis and efficient treatment. Equally important is a thorough metabolic evaluation directing appropriate medical therapy and lifestyle changes to help reduce recurrent stone disease. Without such follow-up and medical intervention, stone recurrence rates can be as high as 50% within 5 years. Uric acid calculi can recur even more frequently. Physicians look forward to gaining a better understanding of this multifactorial disease process in hopes of developing more effective prophylaxis.

### Renal and Ureteral Stones

#### Etiology

Mineralization in all biologic systems has a common theme in that the crystals and matrix are intertwined. Urinary stones are no exception; they are polycrystalline aggregates composed of varying amounts of crystalloid and organic matrix. Theories to explain urinary stone disease are incomplete.

Stone formation requires supersaturated urine. Supersaturation depends on urinary pH, ionic strength, solute concentration, and complexation. Urinary constituents may change dramatically during different physiologic states from a relatively acid urine in a first morning void to an alkaline tide noted after meals. Ionic strength is determined primarily by the relative concentration of monovalent ions. As ionic strength increases, the activity coefficient decreases. The activity coefficient reflects the availability of a particular ion.

The role of solute concentrations is clear: The greater the concentration of two ions, the more likely they are to precipitate. Low ion concentrations result in undersaturation and increased solubility. As ion concentrations increase, their activity product reaches a specific point termed the *solubility product* ( $K_{sp}$ ). Concentrations above this point are metastable and are capable of initiating crystal growth and heterogeneous nucleation. As solutions become more concentrated, the activity product eventually reaches the formation product ( $K_{fp}$ ). Supersaturation levels beyond this point are unstable, and spontaneous homogeneous nucleation may occur.

Multiplying two ion concentrations reveals the concentration product. The concentration products of most ions are greater than established solubility products. Other factors must play major roles in the development of urinary calculi, including complexation. Complexation influences the availability

of specific ions. For instance, sodium complexes with oxalate and decreases its free ionic form, while sulfates can complex with calcium. Crystal formation is modified by a variety of other substances found in the urinary tract, including magnesium, citrate, pyrophosphate, and a variety of trace metals. These inhibitors may act at the active crystal growth sites or as inhibitors in solution (as with citrate).

The nucleation theory suggests that urinary stones originate from crystals or foreign bodies immersed in supersaturated urine. This theory is challenged by the same arguments that support it. Stones do not always form in patients who are hyperexcretors or who are at risk for dehydration. Additionally, up to a third of stone formers' 24-hour urine collections are completely normal with respect to stone-forming ion concentrations.

The crystal inhibitor theory claims that calculi form due to the absence or low concentration of natural stone inhibitors including magnesium, citrate, pyrophosphate, and a variety of trace metals. This theory does not have absolute validity, since many people lacking such inhibitors may never form stones, and others with an abundance of inhibitors may, paradoxically, form them.

## Crystal Component

Stones are composed primarily of a crystalline component. Crystals of adequate size and transparency are easily identified under a polarizing microscope. X-ray diffraction is preferred to assess the geometry and architecture of calculi. A group of stones from the same geographic location or the same historical time period typically have crystalline constituents that are common.

Multiple steps are involved in crystal formation, including nucleation, growth, and aggregation. Nucleation initiates the stone process and may be induced by a variety of substances, including proteinaceous matrix, crystals, foreign bodies, and other particulate tissues. Heterogeneous nucleation (epitaxy), which requires less energy and may occur in less saturated urine, is a common theme in stone formation. It should be suspected whenever an oriented conglomerate is found. A crystal of one type thereby serves as a nidus for the nucleation of another type with a similar crystal lattice. This is frequently seen with uric acid crystals initiating calcium oxalate formation. It takes time for these early nidi to grow or aggregate to form a stone incapable of passing with ease through the urinary tract.

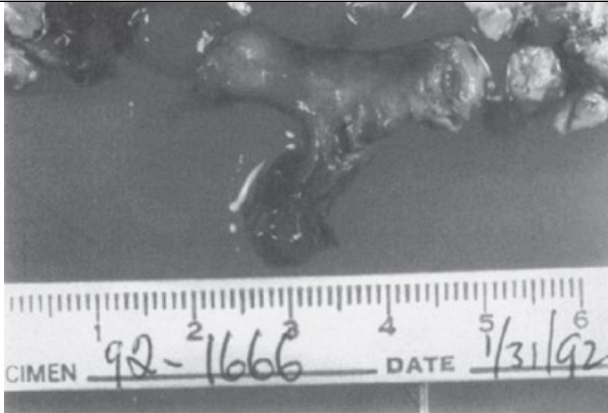How these early crystalline structures are retained in the upper urinary tract without uneventful passage down the ureter is unknown. The theory of mass precipitation or intranephronic calculosis suggests that the distal tubules or collecting ducts, or both, become plugged with crystals, thereby establishing an environment of stasis, ripe for further stone growth. This explanation is unsatisfactory; tubules are conical in shape and enlarge as they enter the papilla (ducts of Bellini), thereby reducing the possibility of ductal obstruction. In addition, urine transit time from the glomerulus into the renal pelvis is only a few minutes, making crystal aggregation and growth within the uriniferous tubules unlikely.

The fixed particle theory postulates that formed crystals are somehow retained within cells or beneath tubular epithelium. Alexander Randall noted whitish-yellow precipitations of crystalline substances occurring on the tips of renal papillae as submucosal plaques. These plaques are associated with both the vasa recta and the urinary collecting ducts and grow deep within the papilla. The tips of the plaques can be appreciated during endoscopy of the upper urinary tract. Carr hypothesized that calculi form in obstructed lymphatics and then rupture into adjacent fornices of a calyx. Arguing against Carr's theory are the grossly visible early stone elements in areas remote from fornices.

## Matrix Component

The amount of the noncrystalline, matrix component of urinary stones varies with stone type, commonly ranging from 2% to 10% by weight. It is composed predominantly of protein, with small amounts of hexose and hexosamine. An unusual type of stone called a matrix calculus can be associated with previous kidney surgery or chronic urinary tract infections and has a gelatinous texture (Figure 17-1). Histologic inspection reveals laminations with scant calcifications. On plain abdominal radiographs, matrix calculi are usually radiolucent and can be confused with other filling defects, including blood clots, upper-tract tumors, and fungal bezoars. Noncontrast computed tomography (CT) reveals calcifications and can help to confirm the diagnosis. The role of matrix in the initiation of ordinary urinary stones as well as matrix stones is unknown. It may serve as a nidus for crystal aggregation or as a naturally occurring glue to adhere small crystal components and thereby hinder uneventful passage down the urinary tract. Alternatively, matrix may have an inhibitory role in stone formation or may be an innocent bystander, playing no active role in stone formation.

Figure 17-1.



Source: McAninch JW, Lue TF: *Smith & Tanagho's General Urology*, 18th Edition:  
[www.accessmedicine.com](http://www.accessmedicine.com)

Copyright © The McGraw-Hill Companies, Inc. All rights reserved.

Gross picture of matrix calculus percutaneously extracted after extracorporeal shock wave lithotripsy failure.

## Urinary Ions

### Calcium

Calcium is a major ion present in urinary crystals. The risk of urinary stones increases as fractional calcium absorption from the gut increases; calcium absorption from the gut decreases with increased calcium intake. Only 50% of plasma calcium is ionized and available for filtration at the glomerulus. More than 95% of the calcium filtered at the glomerulus is reabsorbed at both the proximal and distal tubules and limited amounts in the collecting tube. Less than 2% is excreted in the urine. Diuretic medications may exert a hypocalciuric effect by further decreasing calcium excretion. Many factors influence the availability of calcium in solution, including complexation with citrate, phosphate, and sulfate. An increase in monosodium urates and a decrease in urinary pH further interfere with this complexation and therefore promote crystal aggregation.

### Oxalate

Oxalate is a normal waste product of metabolism and is relatively insoluble. Normally, approximately 10–15% of oxalate found in the urine originates from the diet; the vast majority is a metabolic by-product. Most of the oxalate that enters the large bowel is consumed by bacterial decomposition. *Oxalobacter formigenes* may alter the availability of oxalate absorption. Diet, however, can have an impact on the amount of oxalate found in the urine. Once absorbed from the small bowel, oxalate is not metabolized and is excreted almost exclusively by the proximal tubule. The presence of calcium within the bowel lumen is an important factor influencing the amount of oxalate that is absorbed. The control of oxalate in the urine plays a pivotal role in the formation of calcium oxalate calculi. Normal excretion ranges from 20 to 45 mg/day and does not change significantly with age. Excretion is higher during the day when one eats. Small changes in oxalate levels in the urine can have a dramatic impact on the supersaturation of calcium oxalate. The important precursors of oxalate are glycine and ascorbic acid; however, the impact of ingested vitamin C (<2 g/day) is negligible.

Hyperoxaluria may develop in patients with bowel disorders, particularly inflammatory bowel disease, small-bowel resection, and bowel bypass. Renal calculi develop in 5–10% of patients with these conditions. Chronic diarrhea with fatty stools results in a saponification process. Intraluminal calcium binds to the fat, thereby becoming unavailable to bind to oxalate. The unbound oxalate is readily absorbed from the gut and increases urinary oxalate levels.

Excessive oxalate may occur secondary to the accidental or deliberate ingestion of ethylene glycol (partial oxidation to oxalate). This may result in diffuse and massive deposition of calcium oxalate crystals and may occasionally lead to renal failure.

### Phosphate

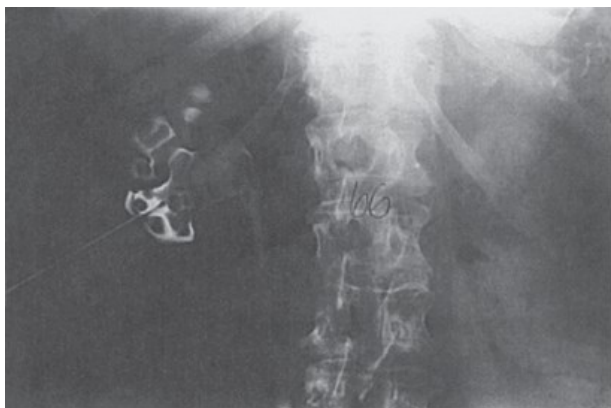
Phosphate is an important buffer and complexes with calcium in urine. It is a key component in calcium phosphate and magnesium ammonium phosphate stones. The excretion of urinary phosphate in normal adults is related to the amount of dietary phosphate (especially in meats, dairy products, and vegetables). The small amount of phosphate filtered by the glomerulus is predominantly reabsorbed in the proximal tubule. Parathyroid

hormone inhibits this reabsorption. The predominant crystal found in patients with hyperparathyroidism is phosphate, in the form of hydroxyapatite, amorphous calcium phosphate, and carbonate apatite.

## Uric Acid

Uric acid is the by-product of purine metabolism. The  $pK_a$  of uric acid is 5.75. Undissociated uric acid predominates with pH values less than this. Elevated pH values increase urate, which is soluble. Approximately 10% of the filtered uric acid finds its way into the urine. Other defects in purine metabolism may result in urinary stone disease. Rarely, a defect in xanthine dehydrogenase results in increased levels of xanthine; the xanthine may precipitate in urine, resulting in stone formation. Unusual alterations in adenine metabolism may result in the production of 2,8-dihydroxyadeninuria, which is poorly soluble in urine and may develop into a urinary stone. This results from a deficiency of adenine phosphoribosyltransferase (APRT). Pure uric acid crystals and calculi are relatively radiolucent and may not be identified on plain abdominal films (Figure 17-2). They are visible on noncontrast CT images and are suggestive when found to have low Hounsfield units (HU). Some uric acid calculi may be partially radiopaque, however, because of associated calcium phosphate deposits.

Figure 17-2.



Source: McAninch JW, Lue TF: *Smith & Tanagho's General Urology*, 18th Edition: [www.accessmedicine.com](http://www.accessmedicine.com)

Copyright © The McGraw-Hill Companies, Inc. All rights reserved.

Radiolucent right staghorn renal calculus appreciated after percutaneous injection of radiocontrast material. This uric acid stone was effectively removed in a single percutaneous procedure. Postoperative urinary alkalinization has been effective prophylaxis.

## Sodium

Although not identified as one of the major constituents of most urinary calculi, sodium plays an important role in regulating the crystallization of calcium salts in urine. Sodium is found in higher than expected concentrations in the core of renal calculi and may play a role in initiating crystal development and aggregation. High dietary sodium intake increases urinary calcium excretion and increases the urinary levels of monosodium urates that promote stone growth. This reduces the ability of urine to inhibit calcium oxalate crystal agglomeration. These effects are thought to be due to a sodium-induced increase in bicarbonaturia and decrease in serum bicarbonate. Interestingly, increased dietary sodium intake increases one's thirst and increases voided volumes. Conversely, a reduction in dietary sodium helps to reduce recurrent calcium nephrolithiasis.

## Citrate

Citrate is a key factor affecting the development of calcium urinary stones. A deficiency commonly is associated with stone formation in those with chronic diarrhea or renal tubular acidosis type I (distal tubular defect) and in patients prescribed chronic thiazide therapy. Citrate plays a pivotal role in the citric acid cycle in renal cells. Metabolic stimuli that consume this product (as with intracellular metabolic acidosis due to fasting, hypokalemia, or hypomagnesemia) reduce the urinary excretion of citrate. Estrogen increases citrate excretion and may be a factor that decreases the incidence of stones in women, especially during pregnancy. Alkalosis also increases citrate excretion.

## Magnesium

Dietary magnesium deficiency is associated with an increased incidence of urinary stone disease. Magnesium is a component of struvite calculi. Experimentally, lack of dietary magnesium is associated with increased calcium oxalate stone formation and calcium oxalate crystalluria. The exact mechanism whereby magnesium exerts its effect is undefined. Dietary magnesium supplements typically do not protect against stone formation.

## Sulfate

Urinary sulfates may help prevent urinary calculi. They can complex with calcium. These sulfates occur primarily as components of longer urinary proteins, such as chondroitin sulfate and [heparin](#) sulfate.

## Other Urinary Stone Inhibitors

Inhibitors of urinary stone formation other than citrate, magnesium, and sulfates have been identified. These consist predominantly of urinary proteins and other macromolecules such as glycosaminoglycans, pyrophosphates, and uropontin. Although citrate appears to be the most active inhibitory component in urine, these substances demonstrate a substantial role in preventing urine crystal formation. The N-terminal amino acid sequence and the acidic amino acid content of these protein inhibitors, especially their high aspartic acid content, appear to play pivotal inhibitory roles. [Fluoride](#) may be an inhibitor of urinary stone formation.

## Stone Varieties

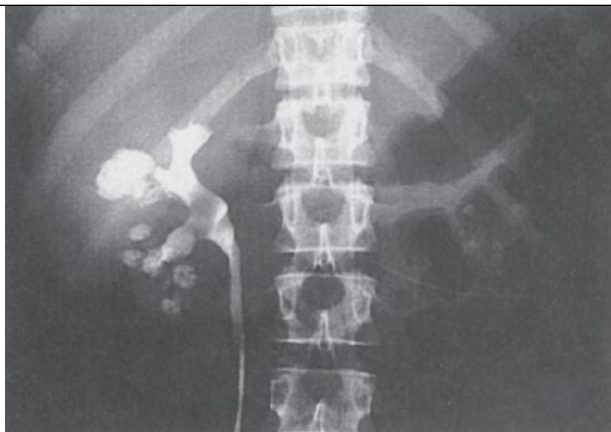
### Calcium Calculi

Calcifications can occur and accumulate in the collecting system, resulting in nephrolithiasis. Eighty to eighty-five percent of all urinary stones are calcareous.

Calcium nephrolithiasis is most commonly due to elevated urinary calcium, elevated urinary uric acid, elevated urinary oxalate, or a decreased level of urinary citrate. Hypercalciuria is found as a solitary defect in 12% of patients and in combination with other defects in an additional 18%. Hyperuricosuria is identified as a solitary defect in 8% of patients and associated with additional defects in 16%. Elevated urinary oxalate is found as a solitary finding in 5% of patients and as a combined defect in 16%. Finally, decreased urinary citrate is found as an isolated defect in 17% of patients and as a combined defect in an additional 10%. Approximately one-third of patients undergoing a full metabolic evaluation will find no identifiable metabolic defect.

Symptoms from stones are secondary to obstruction, with resultant pain, infection, nausea, and vomiting, and rarely culminate in renal failure. Asymptomatic hematuria or repetitive urinary tract infections recalcitrant to apparently appropriate antibiotics should lead one to suspect a possible urinary stone. Calcifications within the parenchyma of the kidney, known as nephrocalcinosis, rarely cause symptoms, however, and usually are not amenable to traditional therapies appropriate for urinary stone disease ([Figure 17-3](#)). Nephrocalcinosis is frequently encountered with renal tubular acidosis and hyperparathyroidism. Nephrolithiasis and nephrocalcinosis frequently coexist. Most patients with nephrolithiasis, however, do not have obvious nephrocalcinosis.

Figure 17-3.



Source: McAninch JW, Lue TF: *Smith & Tanagho's General Urology*, 18th Edition: [www.accessmedicine.com](http://www.accessmedicine.com)

Copyright © The McGraw-Hill Companies, Inc. All rights reserved.

Retrograde pyelogram demonstrating multiple punctate calcifications within the renal parenchyma establishing the diagnosis of nephrocalcinosis. Renal pelvis and infundibula are free of calculi.

Nephrocalcinosis may result from a variety of pathologic states. Ectatic collecting tubules, as seen with medullary sponge kidney, are common; this is frequently a bilateral process. Theoretically, obstructed collecting ducts may be a source of chronic flank pain. Increased calcium absorption from the small bowel is common with sarcoidosis, milk-alkali syndrome, hyperparathyroidism, and excessive vitamin D intake. Disease processes resulting in bony destruction, including hyperparathyroidism, osteolytic lesions, and multiple myeloma, are a third mechanism. Finally, dystrophic calcifications forming on necrotic tissue may develop after a renal insult.

### Absorptive Hypercalciuric Nephrolithiasis

Normal calcium intake averages approximately 900–1000 mg/day. Approximately one-third is absorbed by the small bowel, and of that portion, approximately 150–200 mg is obligatorily excreted in the urine. A large reservoir of calcium remains in the bone. Most dietary calcium is excreted in the stool. Absorptive hypercalciuria is secondary to increased calcium absorption from the small bowel, predominantly from the jejunum. This results in an increased load of calcium filtered from the glomerulus. The result is suppression of parathyroid hormone, leading to decreased tubular reabsorption of calcium, culminating in hypercalciuria (>4 mg/kg). This physiologic cascade is in response to the primary defect, an increased absorption of calcium from the small bowel.

Absorptive hypercalciuria traditionally has been subdivided into three types. Type I absorptive hypercalciuria is independent of diet and represents 15% of all calcareous calculi. There is an elevated urinary calcium level (>150–200 mg/24 hour) even during a calcium-restricted diet. Cellulose phosphate is an effective nonabsorbable exchange resin. This effectively binds the calcium in the gut, preventing bowel absorption. Cellulose phosphate has no impact on the calcium transport defect. Urinary calcium excretion returns to normal values with therapy.

Cellulose phosphate must be taken with meals to be available when calcium is ingested. A typical dose is 10–15 g orally in three divided doses and is well tolerated. This therapy is relatively contraindicated in postmenopausal women and in children during their active growth cycles. Inappropriate use may lead to a negative calcium balance and a secondary hyperparathyroid state. As with all stone formers, long-term follow-up is required. Cellulose phosphate may bind other cations besides calcium, including magnesium. Secondary hyperoxaluria may develop owing to decreased calcium in the gut. See the section on hyperoxaluria for a more detailed discussion.

Hydrochlorothiazides are an alternative, more common treatment for type I absorptive hypercalciuria. Initially, there is a reduction in renal excretion of calcium. The increased absorbed calcium is likely deposited in bone. Eventually, the bone reservoir reaches its capacity and the drug becomes less effective. Hydrochlorothiazides have limited long-term efficacy (approximately 3–5 years). These drugs have no effect on the defective bowel transport system. Hydrochlorothiazides may be alternated with cellulose phosphate as an effective treatment regimen.

Type II absorptive hypercalciuria is dietary dependent. There is no specific medical therapy. Calcium excretion returns to normal on a calcium-restricted diet. These are the rare patients that should limit their calcium intake to 400–600 mg/day. Type II absorptive hypercalciuria is not as severe as



type I.

Type III absorptive hypercalciuria is secondary to a phosphate renal leak and accounts for 5% of all urinary calculi. Decreased serum phosphate leads to an increase in 1,25-dihydroxyvitamin D synthesis. The physiologic cascade culminates in an increased absorption of phosphate, and calcium, from the small bowel and an increased renal excretion of calcium—hence its classification as absorptive hypercalciuria. Successful treatment replaces bioavailable phosphate. Orthophosphate (Neutra-Phos, now available over the counter) inhibits vitamin D synthesis and is best taken as 250 mg three to four times daily. It is best taken after meals and before bedtime. Orthophosphates do not alter intestinal calcium absorption.

### Resorptive Hypercalciuric Nephrolithiasis

A subset (<10%) of patients with clinically obvious primary hyperparathyroidism present with nephrolithiasis. This group represents less than 5% of all patients with urinary stones and are more commonly seen in women. Patients with calcium phosphate stones, women with recurrent calcium stones, and those with both nephrocalcinosis and nephrolithiasis should be suspected of having hyperparathyroidism. Hypercalcemia and an elevated serum parathyroid level are the most consistent signs of hyperparathyroidism.

Parathyroid hormone results in a cascade of events starting with an increase in urinary phosphorus and a decrease in plasma phosphorus, followed by an increase in plasma calcium and a decrease in urinary calcium. Its action on the kidney and on the bone is independent of each other. Ultimately, renal damage is secondary to the hypercalcemia. It limits the concentrating ability of the kidney and impairs the kidney's ability to acidify urine. Surgical removal of the offending parathyroid adenoma is the most effective way of treating this disease. However, up to 25% of these patients will develop new urinary stones after successful surgery, most commonly seen in men. Attempts at long-term medical management are challenging.

### Renal-Induced Hypercalciuric Nephrolithiasis

Hypercalciuria of renal origin is due to an intrinsic renal tubular defect in calcium excretion. This creates a physiologically vicious cycle. Excessive urinary calcium excretion results in a relative decrease in serum calcium, which leads to a secondarily increased parathyroid hormone level that mobilizes calcium from the bone and increases calcium absorption from the gut. This step completes the pathologic cycle by delivering increased levels of calcium back to the kidney, whereby the renal tubules excrete large amounts of calcium. These patients have an elevated fasting urinary calcium level, normal serum calcium level, and a secondarily elevated parathyroid hormone level.

Renal hypercalciuria is effectively treated with hydrochlorothiazides. Unlike their role in type I absorptive hypercalciuria, in this setting hydrochlorothiazides have a durable long-term effect. As a diuretic, they decrease the circulating blood volume and subsequently stimulate proximal tubular absorption of calcium as well as other constituents. They also increase reabsorption at the distal tubule. Both mechanisms correct the secondary hyperparathyroid state.

Hypercalciuric states may result in elevated parathyroid levels. To help differentiate primary hyperparathyroidism from secondary hyperparathyroidism in patients with urinary stone disease, one can prescribe a [hydrochlorothiazide](#) challenge (50 mg twice a day for 7–10 days). Patients with secondary hyperparathyroidism will have a return to normal serum parathyroid levels, while those with primary hyperparathyroidism will continue to have elevated serum values.

### Hyperuricosuric Calcium Nephrolithiasis

Hyperuricosuric calcium nephrolithiasis is due to either an excessive dietary intake of purines or an increase in endogenous uric acid production. In both situations, there is an increase in urinary monosodium urates. Monosodium urates absorb and adsorb urinary stone inhibitors and facilitate heterogeneous nucleation.

Patients have elevated urinary uric acid levels (>600 mg/24 hour in women and >750 mg/24 hour in men) and consistently have a urinary pH >5.5. The urinary pH helps to differentiate hyperuricosuric calcium from hyperuricosuric uric acid stone formation.

Patients with excessive purine oral intake can be successfully treated by changing to a low purine diet. Those with excessive endogenous uric acid production can be treated with [allopurinol](#). [Allopurinol](#) is a xanthine oxidase inhibitor and reduces uric acid synthesis and renal excretion of uric acid. It also inhibits uric acid–calcium oxalate crystallization. [Allopurinol](#) has many potential side effects, including a variety of skin rashes and, rarely, liver toxicity. Potassium citrate is an alternative treatment, especially when associated with hypocitraturia.

## Hyperoxaluric Calcium Nephrolithiasis

Hyperoxaluric calcium nephrolithiasis is secondary to increased urinary oxalate levels ( $>40$  mg/24 hour). It is frequently found in patients with inflammatory bowel disease or other chronic diarrheal states that result in severe dehydration. It is rarely associated with excessive oxalate intake, as seen in poisoning with ethylene glycol or endogenous overproduction.

Chronic diarrheal states alter oxalate metabolism. Malabsorption leads to increased luminal fat and bile salts. Intraluminal gut calcium readily and preferentially binds to fat and bile resulting in a saponification process. The intraluminal gut calcium that normally would have bound to oxalate is thus decreased. The unbound oxalate is readily absorbed and is unaffected by the usual metabolic inhibitors of energy-dependent pumps. Bile salts may increase the passive bowel absorption of oxalate. A small increase in oxalate absorption and subsequent urinary excretion dramatically increases the formation product of calcium oxalate. This increases the potential for heterogeneous nucleation and crystal growth in this metastable environment. All patients with increased urinary excretion of oxalate do not necessarily form calcium oxalate calculi, other factors must be contributory.

Enteric hyperoxaluric calcium nephrolithiasis is successfully treated with oral calcium supplementation. The calcium binds to the intraluminal oxalate and thus limits its absorption. It must be given with meals when the oxalate is present. Other oral cations are effective binders including magnesium supplements. An alternative therapy includes a diet limited to medium-chain fatty acids and triglycerides; however, it is poorly tolerated by patients. Equally difficult is an attempt to alter oxalate intake. Unless large amounts of specific oxalate-rich foods can be excluded, an alternative diet may result in *increased* oxalate levels.

Primary hyperoxaluria is a rare hereditary disease. It is associated with calcium oxalate renal calculi, nephrocalcinosis, and other distant deposits of oxalate, culminating in progressive renal failure and eventual death. Type I is associated with an enzyme deficiency of 2-oxoglutarate:glyoxylate carboligase, resulting in elevated urinary levels of glycolic acid and oxalic acid. Type II has increased excretory levels of l-glyceric acid rather than elevated levels of glycolic acid. It is associated with a d-glycerate dehydrogenase enzyme deficiency. This ultimately results in the accumulation of hydroxy pyruvate, which is eventually converted to oxalate. Oxalate crystal deposits develop rapidly in transplanted kidneys. Combined liver and renal transplantation has cured this previously fatal rare disease.

## Hypocitraturic Calcium Nephrolithiasis

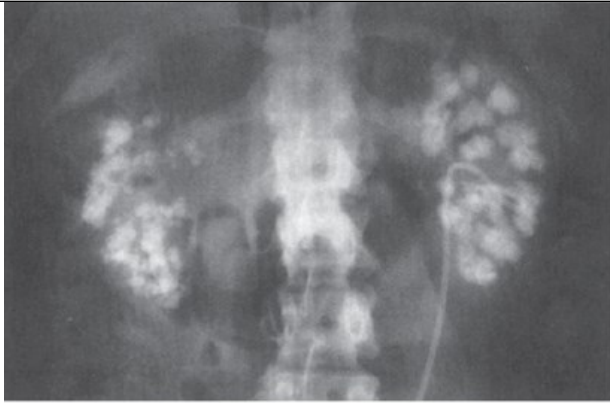Citrate is an important inhibitor of urinary stone disease. Increased metabolic demands on the mitochondria of proximal renal tubular cells decrease the excretion of citrate. Such conditions include intracellular metabolic acidosis, hypokalemia (as with thiazide therapy), fasting, hypomagnesemia, androgens, gluconeogenesis, and an acid-ash diet. Citrate may be consumed in the urine by bacteria during a urinary tract infection. The cause of hypocitraturia may be unknown in some cases. In contrast, alkalosis, alkaline-ash diet, estrogen, and vitamin D increase urinary citrate levels.

Citrate acts in solution and complexes with calcium. This decreases the ionic calcium concentration and thus the activity product. Citrate decreases agglomeration, spontaneous nucleation, and crystal growth of calcium oxalate. It also decreases calcium oxalate calculi by decreasing monosodium urates that can absorb inhibitors and facilitate heterogeneous nucleation.

Hypocitraturic ( $<450$  mg/24 h) calcium nephrolithiasis is associated commonly with renal tubular acidosis type I (distal tubule) (Figure 17-4), thiazide therapy (accompanied by potassium wastage), and chronic diarrhea. Treatment is successful with potassium citrate supplementation. Routine dosage is 20–30 mEq two to three times daily (tablet, crystal or liquid preparation) and is usually well tolerated. Six to eight glasses of lemonade can increase urinary citrate excretion by approximately 150 mg/24 h and thus either limit or eliminate the need for pharmacologic citrate supplementation.

Figure 17-4.





Source: McAninch JW, Lue TF: *Smith & Tanagho's General Urology*, 18th Edition: [www.accessmedicine.com](http://www.accessmedicine.com)

Copyright © The McGraw-Hill Companies, Inc. All rights reserved.

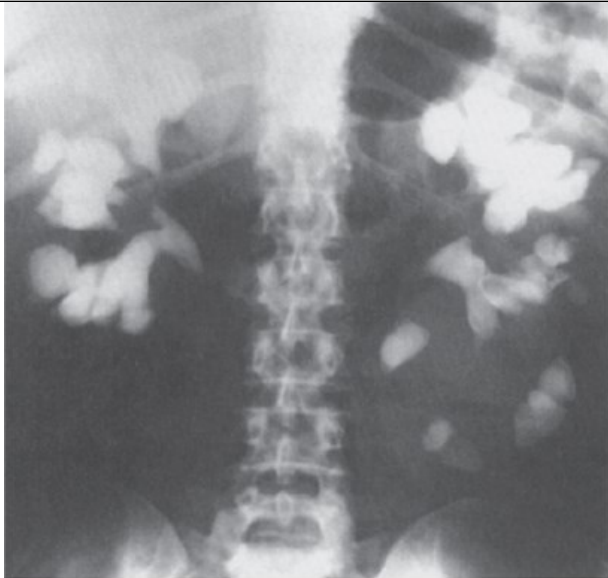
Scout abdominal radiograph demonstrating bilateral, multiple renal calculi in a patient with renal tubular acidosis, type I.

## Noncalcium Calculi

### Struvite

Struvite stones are composed of magnesium, ammonium, and phosphate (MAP). They are found most commonly in women and may recur rapidly. They frequently present as renal staghorn configured calculi (branched with stones occupying the renal pelvis and at least to renal infundibuli) and rarely present as obstructing ureteral stones except after surgical intervention ([Figure 17-5](#)). Struvite stones are infection stones associated with urea-splitting organisms, including *Proteus*, *Pseudomonas*, *Providencia*, *Klebsiella*, *Staphylococci*, and *Mycoplasma*. The high ammonium concentration derived from the urea-splitting organisms results in an alkaline urinary pH. The urinary pH of a patient with a MAP stone rarely is <7.2 (normal urinary pH is 5.85). It is only at this elevated urinary pH (>7.19) that MAP crystals precipitate. MAP crystals are soluble in the normal urinary pH range of 5–7. Preoperative bladder cultures do not necessarily reflect the bacteriologic composition found in calculi. Foreign bodies and neurogenic bladders may predispose patients to urinary infections and subsequent struvite stone formation. Massive diuresis does not prevent struvite calculi. Women with recurrent non-*Escherichia coli* urinary infections despite apparently appropriate antibiotic therapy should be evaluated for struvite calculi with a conventional kidney-ureter-bladder (KUB) radiograph or renal ultrasound, or both. It is impossible to sterilize such calculi with antibiotics. Culture-specific antibiotics can reduce urease levels and help reduce stone recurrence. Stone removal is therapeutic.

Figure 17-5.



Source: McAninch JW, Lue TF: *Smith & Tanagho's General Urology*, 18th Edition: [www.accessmedicine.com](http://www.accessmedicine.com)

Copyright © The McGraw-Hill Companies, Inc. All rights reserved.

Scout abdominal radiograph demonstrating large bilateral struvite staghorn calculi. Patient was treated for many years with numerous antibiotics for recurrent urinary tract infections. Only after this radiograph were calculi identified and removed and the infections resolved.

Long-term management is optimized with the removal of all foreign bodies, including catheters of all varieties. A short ileal loop urinary diversion helps decrease the risk of stones in those with supravescicular urinary diversion. All stone fragments should be removed with or without the aid of follow-up irrigations. Hemiacidrin (Renacidin) irrigations should be used with caution if at all. Rapid magnesium toxicity can result in death even with a low-pressure irrigation setup (<20 cm water pressure) and negative daily urine cultures. Acetohydroxamic acid inhibits the action of bacterial urease, thereby reducing the urinary pH and decreasing the likelihood of precipitation. Most patients have a difficult time tolerating this medication.

## Uric Acid

Uric acid stones comprise <5% of all urinary calculi and are usually found in men. Patients with gout, myeloproliferative diseases, or rapid weight loss and those treated for malignant conditions with cytotoxic drugs have an increased incidence of uric acid lithiasis. Most patients with uric acid calculi, however, do not have hyperuricemia. Elevated urinary uric acid levels are frequently due to dehydration and excessive purine intake. Patients present with a urinary pH consistently <5.5, in contrast to patients with hyperuricosuric calcium nephrolithiasis, who have a urinary pH >5.5. As the urinary pH increases above the dissociation constant  $pK_a$  of 5.75, it dissociates into a relatively soluble urate ion. Treatment is centered on maintaining a urine volume >2 L/day and a urinary pH >6.0. Reducing dietary purines or the administration of [allopurinol](#) also helps reduce uric acid excretion. Alkalinization, however, is the mainstay of therapy (with oral sodium bicarbonate, potassium bicarbonate, potassium citrate, or intravenous 1/6 normal sodium lactate) and may dissolve calculi (the rate of dissolution is dependent on the stone surface area). Stone fragments after lithotripsy have a dramatically increased surface area compared with intact stones and thus will dissolve more rapidly. Dissolution proceeds at approximately 1 cm of stone (as seen on KUB) per month, with compliant alkalinization.

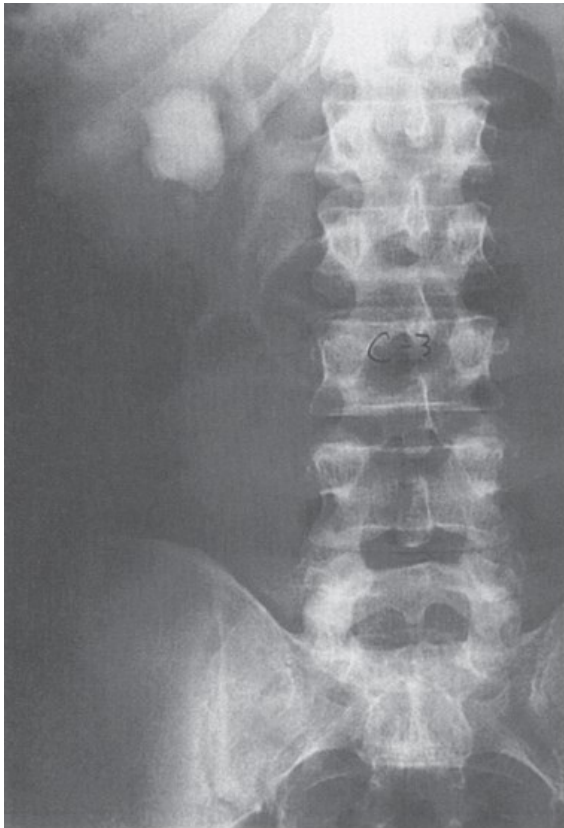## Cystine

Cystine lithiasis is secondary to an inborn error of metabolism resulting in abnormal intestinal (small bowel) mucosal absorption and renal tubular absorption of dibasic amino acids, including cystine, ornithine, lysine, and [arginine](#). The genetic defects associated with cystinuria have now been mapped to chromosome 2p.16 and more recently to 19q13.1. Cystine lithiasis is the only clinical manifestation of this defect. Classic cystinuria is inherited in an autosomal recessive fashion. Homozygous expression has a prevalence of 1:20,000, while the heterozygous expression is 1:2000. It represents 1–2% of all urinary stones, with a peak incidence in the second or third decade. Homozygous cystinurics excrete more than 250 mg/day, resulting in constant supersaturation. Heterozygous patients usually excrete 100–150 mg/day. Unaffected patients typically excrete <40 mg/day. Approximately 400 mg/L of cystine can remain in solution at a urinary pH of 7.0. As the urinary pH increases above 7.0, the amount of soluble cystine

increases exponentially.

The solubility of cystine is pH dependent, with a  $pK$  of approximately 8.1. There is no difference in the solubility curves in normal versus patients with cystinuria. There is no known inhibitor for cystine calculi, and cystine stone formation is completely dependent on excessive cystine excretion. Cystine stones are frequently associated with calcium calculi and their related metabolic abnormalities. They may present as single, multiple, or staghorn configured stones. The diagnosis is suspected in patients with a family history of urinary stones and the radiographic appearance of a faintly opaque, ground-glass, smooth-edged stone (Figure 17-6). Urinalysis frequently reveals hexagonal crystals. The stones have an amber color. Stone analysis confirms the diagnosis. Quantitative urinary cystine evaluation helps confirm the diagnosis and differentiate heterozygous from homozygous states. It is also important to help titrate medical therapy.

Figure 17-6.



Source: McAninch JW, Lue TF: *Smith & Tanagho's General Urology*, 18th Edition: [www.accessmedicine.com](http://www.accessmedicine.com)

Copyright © The McGraw-Hill Companies, Inc. All rights reserved.

Scout radiograph demonstrating a right cystine calculus. Note ground-glass appearance with smooth edges.

Medical therapy includes high fluid intake (>3 L/d, day and night) and urinary alkalinization. Patients should monitor their pH with Nitrazine indicator paper and keep their pH values above 7.5. It is difficult or impossible to maintain levels >8.0. A low-methionine (precursor to cystine) diet has limited impact, as most of the cystine is endogenous and most of the ingested methionine is incorporated into protein. [Glutamine](#), ascorbic acid, and [captopril](#) are effective in some patients. [Penicillamine](#) can reduce urinary cystine levels. It complexes with the amino acid, and this complex is dramatically more soluble. Treatment should be titrated with quantitative urinary cystine values. Many patients poorly tolerate [penicillamine](#), reporting skin rashes (discrete or confluent macules with occasional itching), loss of taste, nausea, vomiting, and anorexia. It may inhibit [pyridoxine](#), which should be supplemented during treatment (50 mg/d). Mercaptopropionylglycine (Thiola), 300–1200 mg in divided doses, with initial dosing matched with total quantitative cystine excretion (mg per mg) forms a soluble complex with cystine and can reduce stone formation and is the most commonly used sulfide-binding drug. Side effects and frequent dosing, however, decrease patient compliance.

Surgical treatment is similar to that for other stones except that most stones are recalcitrant to extracorporeal shock wave lithotripsy (SWL). One

should have a low threshold to proceed with percutaneous stone extraction in symptomatic patients. Despite optimum medical therapy, a high stone recurrence rate frequently frustrates both patient and physician. Minimally invasive techniques and optimum medical therapy are paramount.

### Xanthine

Xanthine stones are secondary to a congenital deficiency of xanthine dehydrogenase. This enzyme normally catalyzes the oxidation of hypoxanthine to xanthine and of xanthine to uric acid. It is of interest that [allopurinol](#), used to treat hyperuricosuric calcium nephrolithiasis and uric acid lithiasis, produces iatrogenic xanthinuria. Blood and urine levels of uric acid are lowered, and hypoxanthine and xanthine levels are increased; however, there are no case reports of xanthine stone formation resulting from [allopurinol](#) treatment. It is unlikely that [allopurinol](#) completely inhibits xanthine dehydrogenase. Urinary stones develop in approximately 25% of patients with this enzymatic deficiency. The stones are radiolucent and are tannish yellow in color. Treatment should be directed by symptoms and evidence of renal obstruction. High fluid intake and urinary alkalinization are required for prophylaxis. If stones recur, a trial of [allopurinol](#) and a purine-restricted diet is appropriate.

### Indinavir

Protease inhibitors are a popular and effective treatment in patients with acquired immunodeficiency syndrome. [Indinavir](#) is the most common protease inhibitor that results in radiolucent stones in up to 6% of patients who are prescribed this medication. [Indinavir](#) calculi are the only urinary stones to be radiolucent on noncontrast CT scans. They may be associated with calcium components and in these situations will be visible on noncontrast CT images. Temporary cessation of the medication with intravenous hydration frequently allows these stones to pass. The stones are tannish red and usually fall apart during basket extraction.

### Rare

Silicate stones are very rare and are usually associated with long-term use of antacids containing silica. Surgical treatment is similar to that of other calculi.

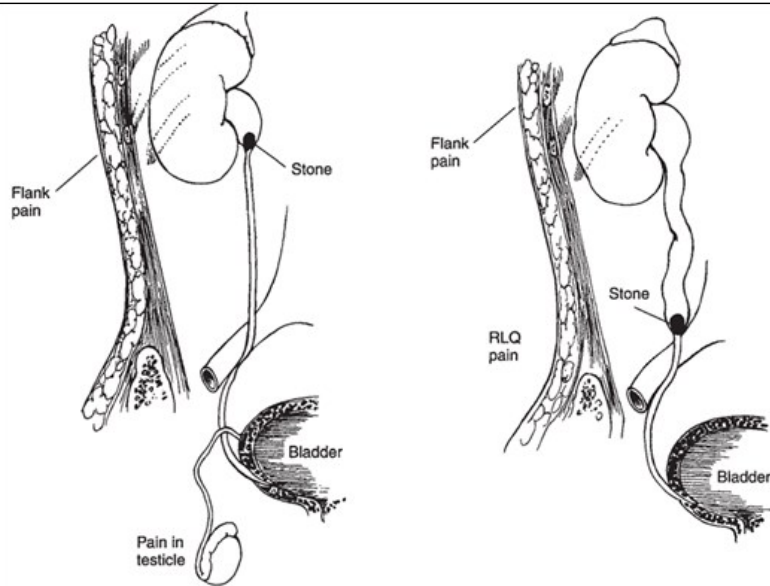
[Triamterene](#) stones are radiolucent and have been identified with an increased frequency. They are associated with antihypertensive medications containing [triamterene](#), such as Dyazide. Discontinuing the medication eliminates stone recurrences. Other medications that may become stone constituents include glafenine and antrafenine.

Rarely, patients arrive at an emergency room at an odd hour feigning signs and symptoms of passing a urinary stone in hopes of obtaining pain medications. They may add blood to their urine and give a believable story of a severe allergy to intravenous contrast medium. Occasionally, patients present a fake urinary stone, with specks of paint or other obvious curiosities. Such patients have Munchausen syndrome, and the diagnosis is difficult and made by exclusion.

## Symptoms and Signs at Presentation

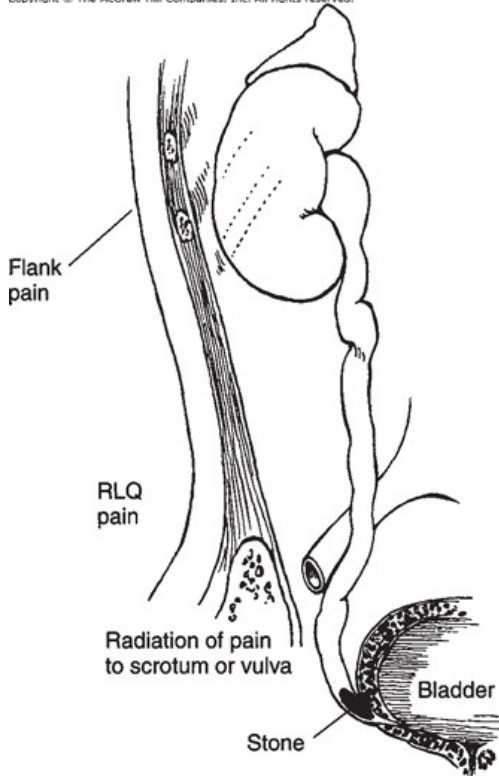
Upper-tract urinary stones frequently cause pain when passing down the ureter. The character of the pain depends on the location. Calculi small enough to venture down the ureter usually have difficulty passing through the ureteropelvic junction, or entering the bladder at the ureterovesical junction ([Figure 17-7](#)). More than 60% of patients presenting with ureteral colic will have stones within 3 cm of the ureterovesical junction.

Figure 17-7.



Source: McAninch JW, Lue TF: *Smith & Tanagho's General Urology*, 18th Edition:  
www.accessmedicine.com

Copyright © The McGraw-Hill Companies, Inc. All rights reserved.



Source: McAninch JW, Lue TF: *Smith & Tanagho's General Urology*, 18th Edition:  
www.accessmedicine.com

Copyright © The McGraw-Hill Companies, Inc. All rights reserved.

Radiation of pain with various types of ureteral stone. **Upper left:** Ureteropelvic stone. Severe costovertebral angle pain from capsular and pelvic distention; acute renal and urethral pain from hyperperistalsis of smooth muscle of calyces, pelvis, and ureter, with pain radiating along the course of the ureter (and into the testicle, since the nerve supply to the kidney and testis is the same). The testis is hypersensitive. **Upper right:** Mid ureteral stone. Same as described earlier but with more pain in the lower abdominal quadrant. **Left:** Low ureteral stone. Same as described earlier, with pain radiating into bladder, vulva, or scrotum. The scrotal wall is hyperesthetic. Testicular sensitivity is absent. When the stone approaches the bladder, urgency and frequency with burning on urination develop as a result of inflammation of the bladder wall around the ureteral orifice.

## Pain

Renal colic and noncolicky renal pain are the two types of pain originating from the kidney. Renal colic usually is caused by stretching of the collecting system or ureter, whereas noncolicky renal pain is caused by distention of the renal capsule. These symptoms may overlap, making a clinical differentiation difficult or impossible. Urinary obstruction is the main mechanism responsible for renal colic. This may be mimicked by the pain a patient experiences when a retrograde ureteropyelogram is performed under local anesthesia, with excessive pressure resulting in overdistention of the collecting system. This pain is due to a direct increase in intraluminal pressure, stretching nerve endings.

Renal colic does not always wax and wane or come in waves like intestinal or biliary colic but may be relatively constant. Renal colic implies an intraluminal origin. Patients with renal calculi have pain primarily due to urinary obstruction.

Local mechanisms such as inflammation, edema, hyperperistalsis, and mucosal irritation may contribute to the perception of pain in patients with renal calculi. In the ureter, however, local pain is referred to the distribution of the ilioinguinal nerve and the genital branch of the genitofemoral nerve, whereas pain from obstruction is referred to the same areas as for collecting system calculi (flank and costovertebral angle), thereby allowing discrimination.

The vast majority of urinary stones present with the acute onset of pain due to acute obstruction and distention of the upper urinary tract. The severity and location of the pain can vary from patient to patient due to stone size, stone location, degree of obstruction, acuity of obstruction, and variation in individual anatomy (eg, intrarenal vs extrarenal pelvis). The stone burden does not correlate with the severity of the symptoms. Small ureteral stones frequently present with severe pain, whereas large staghorn configured calculi may present with a dull ache or flank discomfort.

The pain frequently is abrupt in onset and severe, and may awaken a patient from sleep. The severity of the pain is worsened by the unexpected nature of its onset. Patients frequently move constantly into unusual positions in an attempt to relieve the pain. This movement is in contrast to the lack of movement of someone with peritoneal signs; such a patient lies in a stationary position.

The symptoms of acute renal colic depend on the location of the calculus; several regions may be involved: renal calyx, renal pelvis, upper and mid ureter, and distal ureter. An orderly progression of symptoms as a stone moves down the urinary tract is the exception.

### Renal Calyx

Stones or other objects in calyces or caliceal diverticula may cause obstruction and renal colic. In general, nonobstructing stones cause pain only periodically, owing to intermittent obstruction. The pain is a deep, dull ache in the flank or back that can vary in intensity from severe to mild. The pain may be exacerbated after consumption of large amounts of fluid. Radiographic imaging may not reveal evidence of obstruction despite the patient's complaints of intermittent symptoms. It remains unclear how much of this pain is related to local mucosal irritation with activation of chemoreceptors. The presence of infection or inflammation in the calyx or diverticulum (eg, milk of calcium) in addition to obstruction may contribute to pain perception. Caliceal calculi occasionally result in spontaneous perforation with urinoma, fistula, or abscess formation.

Caliceal calculi are frequently small and numerous and appear to be able to pass spontaneously. Long-term retention against the flow of urine and against the forces of gravity and antegrade peristalsis suggests a significant element of obstruction. Effective long-term treatment requires stone extraction and elimination of the obstructive component.

Pain relief has been reported in many patients following SWL for small symptomatic caliceal calculi. Thus, if a patient continues to complain of pain in the face of a small caliceal calculus, SWL treatment may be justified for both diagnosis and treatment. Percutaneous, retrograde, and laparoscopic techniques have been successful in the management of calculi in calyces or caliceal diverticula.

### Renal Pelvis

Stones in the renal pelvis >1 cm in diameter commonly obstruct the ureteropelvic junction, generally causing severe pain in the costovertebral angle, just lateral to the sacrospinalis muscle and just below the 12th rib. This pain may vary from dull to excruciatingly sharp and is usually constant, boring, and difficult to ignore. It often radiates to the flank and also anteriorly to the upper ipsilateral abdominal quadrant. It may be confused with biliary colic or cholecystitis if on the right side and with gastritis, acute pancreatitis, or peptic ulcer disease if on the left, especially if the patient has associated anorexia, nausea, or emesis. Acquired or congenital ureteropelvic junction obstruction may cause a similar constellation of symptoms. Symptoms



frequently occur on an intermittent basis following a drinking binge or consumption of large quantities of fluid.

Partial or complete staghorn configured calculi that are present in the renal pelvis are not necessarily obstructive. In the absence of obstruction, these patients often have surprisingly few symptoms such as flank or back pain. Recurrent urinary tract infections frequently culminate in radiographic evaluation with the discovery of a large calculus. If untreated, these “silent” staghorn calculi can often lead to significant morbidity, including renal deterioration, infectious complications, or both.

### Upper and Mid-Ureter

Stones or other objects in the upper or mid ureter often cause severe, sharp back (costovertebral angle) or flank pain. The pain may be more severe and intermittent if the stone is progressing down the ureter and causing intermittent obstruction. A stone that becomes lodged at a particular site may cause less pain, especially if it is only partially obstructive. Stationary calculi that result in high-grade but constant obstruction may allow autoregulatory reflexes and pyelovenous and pyelolymphatic backflow to decompress the upper tract, with diminution in intraluminal pressure gradually easing the pain. Pain associated with ureteral calculi often projects to corresponding dermatomal and spinal nerve root innervation regions. The pain of upper ureteral stones thus radiates to the lumbar region and flank. Midureteral calculi tend to cause pain that radiates caudally and anteriorly toward the mid and lower abdomen in a curved, band-like fashion. This band initially parallels the lower costal margin but deviates caudad toward the bony pelvis and inguinal ligament. The pain may mimic acute appendicitis if on the right or acute diverticulitis if on the left side, especially if concurrent gastrointestinal symptoms are present.

### Distal Ureter

Calculi in the lower ureter often cause pain that radiates to the groin or testicle in males and the labia majora in females. This referred pain is often generated from the ilioinguinal or genital branch of the genitofemoral nerves. Diagnosis may be confused with testicular torsion or epididymitis. Stones in the intramural ureter may mimic cystitis, urethritis, or prostatitis by causing suprapubic pain, urinary frequency and urgency, dysuria, stranguria, or gross hematuria. Bowel symptoms are not uncommon. In women, the diagnosis may be confused with menstrual pain, pelvic inflammatory disease, and ruptured or twisted ovarian cysts. Strictures of the distal ureter from radiation, operative injury, or previous endoscopic procedures can present with similar symptoms. This pain pattern is likely due to the similar innervation of the intramural ureter and bladder.

### Hematuria

A complete urinalysis helps to confirm the diagnosis of a urinary stone by assessing for hematuria and crystalluria and documenting urinary pH. Patients frequently admit to intermittent gross hematuria or occasional tea-colored urine (old blood). Most patients will have at least microhematuria. Rarely (in 10–15% of cases), complete ureteral obstruction presents without microhematuria.

### Infection

Magnesium ammonium phosphate (struvite) stones are synonymous with infection stones. They are commonly associated with *Proteus*, *Pseudomonas*, *Providencia*, *Klebsiella*, and *Staphylococcus* infections. They are rarely, if ever, associated with *E. coli* infections. Calcium phosphate stones are the second variety of stones associated with infections. Calcium phosphate stones with a urine pH <6.4 are frequently referred to as brushite stones, whereas infectious apatite stones have a urinary pH >6.4. Rarely, matrix stones with minimal crystalline components are associated with urinary tract infections. All stones, however, may be associated with infections secondary to obstruction and stasis proximal to the offending calculus. Culture-directed antibiotics should be administered before elective intervention.

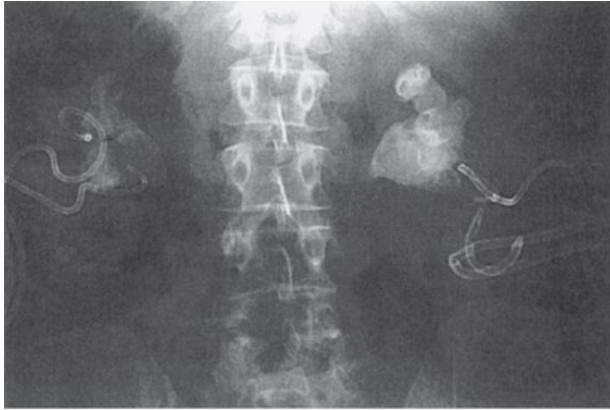
Infection may be a contributing factor to pain perception. Uropathogenic bacteria may alter ureteral peristalsis by the production of exotoxins and endotoxins. Local inflammation from infection can lead to chemoreceptor activation and perception of local pain with its corresponding referral pattern.

### Pyonephrosis

Obstructive calculi may culminate in the development of pyonephrosis. Unlike pyelonephritis, pyonephrosis implies gross purulent urine in an obstructed collecting system. It is an extreme form of infected hydronephrosis. Presentation is variable and may range from asymptomatic bacteriuria to florid urosepsis. Bladder urine cultures may be negative. Radiographic investigations are frequently nondiagnostic. Renal ultrasonography may be

misguiding because of the nonspecific and variable appearance of pyonephrosis. Renal urine aspiration is the only way to make the definitive diagnosis. If the condition is noted at the time of a percutaneous nephrolithotomy, the procedure should be aborted to allow for adequate percutaneous drainage and treatment with appropriate intravenous antibiotics (Figure 17-8). If unrecognized and untreated, pyonephrosis may develop into a renocutaneous fistula.

Figure 17-8.



Source: McAninch JW, Lue TF: *Smith & Tanagho's General Urology*, 18th Edition: [www.accessmedicine.com](http://www.accessmedicine.com)

Copyright © The McGraw-Hill Companies, Inc. All rights reserved.

Bilateral renal calculi seen on scout radiograph with numerous bilateral percutaneous nephrostomy tubes to drain severe bilateral pyonephrosis.

### Xanthogranulomatous Pyelonephritis

Xanthogranulomatous pyelonephritis is associated with upper-tract obstruction and infection. Ultimately, this is a pathologic diagnosis with characteristic foamy macrophages. One-third of patients present with calculi; two-thirds present with flank pain, fever, and chills. Fifty percent of patients present with persistent bacteriuria. Urinalysis usually shows numerous red and white cells. This condition is a common imitator of other pathologic states of the kidney. It usually presents in a unilateral fashion. Laparoscopic or open surgical procedures, such as a simple nephrectomy for minimal or nonrenal function, can be challenging owing to marked and extensive reactive tissues.

### Associated Fever

The association of urinary stones with fever is a relative medical emergency. Signs of clinical sepsis are variable and include fever, tachycardia, hypotension, and cutaneous vasodilation. Costovertebral angle tenderness may be marked with acute upper-tract obstruction; however, it cannot be relied upon to be present in instances of long-term obstruction. In such instances, a mass may be palpable resulting from a grossly hydronephrotic kidney. Fever associated with urinary tract obstruction requires prompt decompression. This may be accomplished with a retrograde catheter (double-J, or an externalized variety to serve as a port for selective urine collections, injection of contrast material, or both). If retrograde manipulations are unsuccessful, insertion of a percutaneous nephrostomy tube is required.

### Nausea and Vomiting

Upper-tract obstruction is frequently associated with nausea and vomiting. Intravenous fluids are required to restore a euvolemic state. Intravenous fluids should not be used to force a diuresis in an attempt to push a ureteral stone down the ureter. Effective ureteral peristalsis requires coaptation of the ureteral walls and is most effective in a euvolemic state.

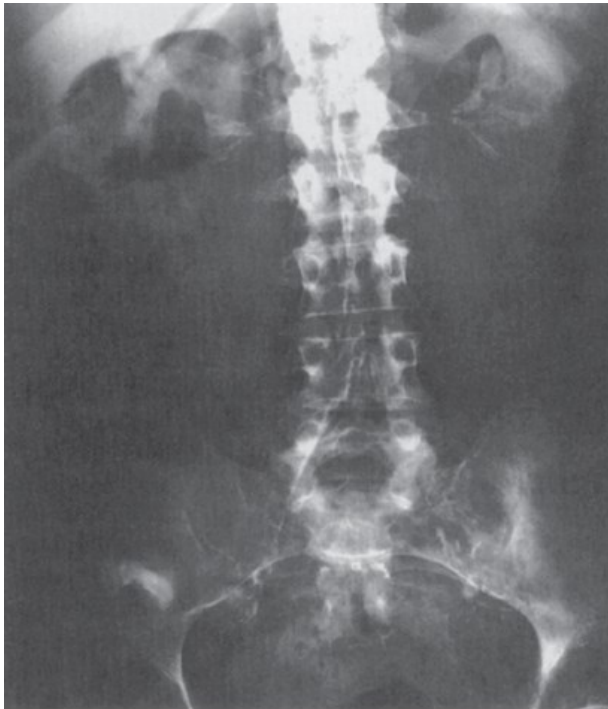
## Special Situations

### Renal Transplantation

Urinary stones associated with renal transplantation are rare. Perirenal nerves are severed at the time of renal harvesting. Classic renal colic is not

found in these patients. The patients usually are admitted with the presumptive diagnosis of graft rejection. Only after appropriate radiographic and ultrasonic evaluation, the correct diagnosis is made (Figure 17-9).

Figure 17-9.



Source: McAninch JW, Lue TF: *Smith & Tanagho's General Urology*, 18th Edition: [www.accessmedicine.com](http://www.accessmedicine.com)

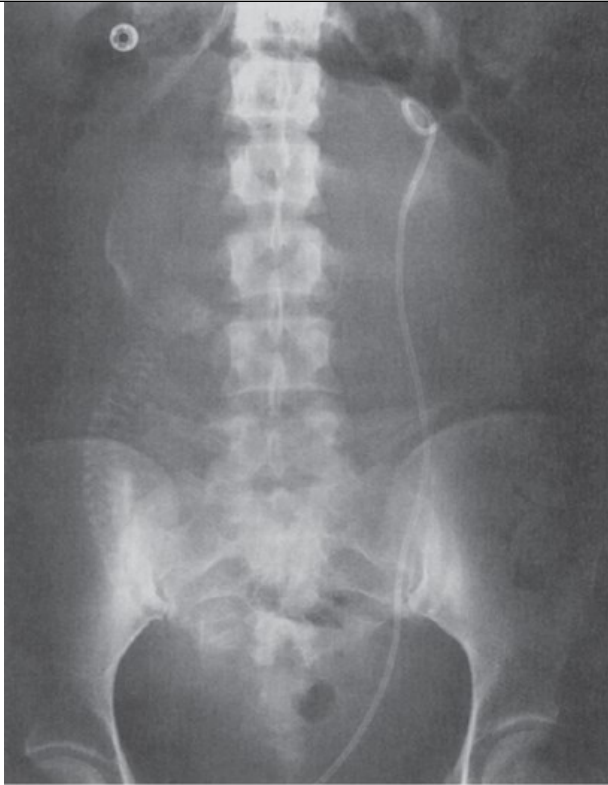Copyright © The McGraw-Hill Companies, Inc. All rights reserved.

Scout abdominal radiograph demonstrating renal calculus in a renal transplant in the right iliac fossa. Note native renal vasculature with marked calcifications secondary to malignant diabetes mellitus.

## Pregnancy

Renal colic is the most common nonobstetric cause of acute abdominal pain during pregnancy (Figure 17-10). Despite marked hypercalciuria associated with pregnancy, calculi are relatively rare, with an incidence approximating 1:1500 pregnancies. Women with known urinary stone disease do not have an increased risk of stones during pregnancy. The increased filtered load of calcium, uric acid, and sodium from the 25–50% increase in glomerular filtration rate associated with pregnancy has been thought to be a responsible factor in stone development.

Figure 17-10.



Source: McAninch JW, Lue TF: *Smith & Tanagho's General Urology*, 18th Edition: [www.accessmedicine.com](http://www.accessmedicine.com)

Copyright © The McGraw-Hill Companies, Inc. All rights reserved.

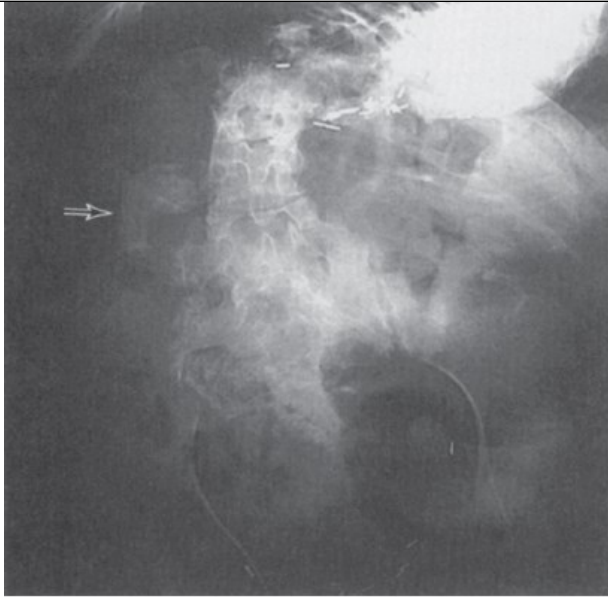
Scout radiograph demonstrating left renal calculus with double-J ureteral stent in place. Skeletal fetal structures can be appreciated in this pregnant patient.

The fetus demands special considerations regarding the potential dangers of radiation exposure (especially during the first trimester), medications, anesthesia, and surgical intervention. About 90% of symptomatic calculi present during the second and third trimesters. Initial investigations can be undertaken with renal ultrasonography and limited abdominal x-rays with appropriate shielding. Treatment requires balancing the safety of the fetus with the health of the mother. Temporizing measures to relieve upper-tract obstruction with a double-J ureteral stent or a percutaneous nephrostomy tube can be performed under local anesthesia. Treatment usually can be delayed until after delivery.

## Dysmorphism

Patients with severe skeletal dysmorphism that is either congenital (spina bifida, myelomeningocele, cerebral palsy) or acquired (arthritis, traumatic spinal cord injuries) and concurrent urinary calculi represent a unique clinical situation requiring special considerations (Figure 17-11). These skeletal abnormalities may preclude appropriate positioning for SWL or percutaneous approaches. Calculi on the concave side in a patient with severe scoliosis may eliminate percutaneous puncture access between the rib and the posterosuperior iliac spine. Retrograde manipulations may need to be performed with flexible endoscopes due to marked contractures, making conventional dorsal lithotomy positioning impossible. Many such patients have undergone suprapubic urinary diversion so that retrograde access may be limited. Risks that need to be addressed include hypercalciuria associated with immobilization, relative dehydration due to patients' or attendants' attempts to reduce urinary output into external collecting devices, and the potential inability to drink without assistance. A full metabolic evaluation is even more important because these social and physical restrictions may be difficult or impossible to remedy.

Figure 17-11.



Source: McAninch JW, Lue TF: *Smith & Tanagho's General Urology*, 18th Edition: [www.accessmedicine.com](http://www.accessmedicine.com)

Copyright © The McGraw-Hill Companies, Inc. All rights reserved.

Scout abdominal radiograph demonstrating a right renal calculus (*arrow*) in a patient with severe kyphoscoliosis. Respiratory compromise limited patient positioning for surgery.

## Obesity

Obesity is a major risk factor for the development of urinary calculi. Surgical bypass procedures can cause hyperoxaluria. Massive weight gain or loss also may precipitate stone development. Obesity limits diagnostic and treatment options. A large pannus may limit the physical examination and misguide incisions. Ultrasound examination is hindered by the attenuation of ultrasound beams. CT scan, magnetic resonance imaging, fluoroscopy tables, and lithotripters all have weight limitations, and patients weighing more than 300 pounds may be unsuited for diagnosis and treatment with these resources. Standard lithotripters have focal lengths <15 cm between the energy source and the F2 target, frequently making treatment of obese patients challenging. A large anterior pannus limits prone positioning on lithotripters. Standard Amplatz nephrostomy sheaths may not be long enough to enter the collecting system. Such sheaths may need to be advanced well below the skin or specialized long sheaths with long nephroscopes may be required. A preplaced heavy suture eases removal of such sheaths.

Risks of anesthesia are increased and special high-pressure respirators may be required if patients are placed in a prone position for a percutaneous procedure. Careful positioning for open procedures helps to reduce the likelihood of crush injuries and associated rhabdomyolysis. These patients are at increased risk of anesthetic complications. Postoperative prophylaxis for thromboembolic complications should be considered.

## Medullary Sponge Kidney

Medullary sponge kidney is a common condition characterized by tubular ectasia associated with parenchymal cysts and clefts that predispose to nephrolithiasis in 50% of affected patients. It is most often an asymptomatic condition; however, it may present with renal colic, hematuria, or urinary tract infection. It is a radiographic diagnosis. The condition can involve select papillae or, more frequently, can be global. A full metabolic evaluation helps direct appropriate medical therapy.

## Renal Tubular Acidosis

There are three main types of renal tubular acidosis: types I, II, and IV. Type I is associated with renal calculi.

Patients with type I renal tubular acidosis present with persistent acidemia with a low serum bicarbonate value unexplained by hyperventilation or known renal failure. The diagnosis should be suspected in those with a known family history, severe hypocitraturia, nephrocalcinosis, medullary sponge kidney, or a fasting urine pH >6.0 in the absence of infection. Patients usually present with nephrolithiasis (calcium phosphate),

nephrocalcinosis, or osteomalacia (or a combination). This disease can be acquired as an adult or inherited with an autosomal dominant pattern. The diagnosis is confirmed by assessing the patient's response to an acid load. This is frequently produced by a rapid oral ammonium chloride load (0.1 g/kg over 1 hour). The dose can be given before bedtime in the evening; the patient is instructed to fast until a second morning voided urine sample and a serum bicarbonate level are obtained. A normal person responds by eliminating the acid load in the urine, resulting in a urinary pH <5.3. Those who do not respond in this fashion can be said to have type I renal tubular acidosis. In addition, the diagnosis should be challenged in those with normal citrate values. Treatment is centered on base replacement with potassium citrate or potassium bicarbonate solutions. Urinary citrate levels can be used to monitor effective treatment.

## Associated Tumors

Squamous cell carcinoma of the upper urinary tract is uncommon but has been associated with calculi. Chronic irritation from calculi or infection may be contributory factors. Upper-tract calculi may predispose patients to transitional cell carcinoma.

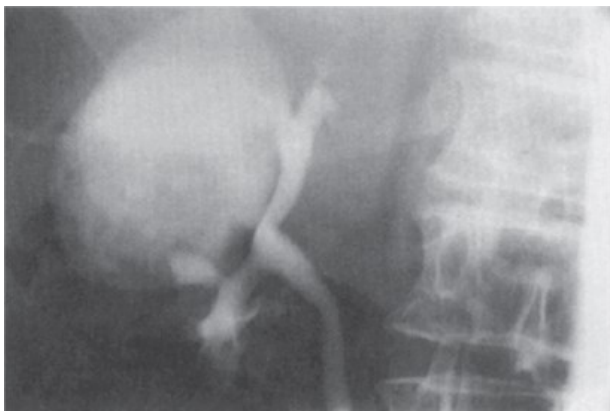
## Pediatric Patients

Urinary calculi are unusual in children. A full and thorough metabolic evaluation should be undertaken. Stone analysis is particularly helpful in directing these investigations. Children born prematurely and given [furosemide](#) while in the neonatal intensive care unit are at increased risk of developing urinary stone disease. Treatment may be limited by endoscope size. Preliminary data show no change in renal growth after SWL.

## Caliceal Diverticula

Pyelocaliceal diverticula are cystic urine-containing eventrations of the upper tract lying within the renal parenchyma; they communicate through a narrow channel into the main collecting system ([Figure 17–12](#)). These diverticula occur in approximately 0.2–0.5% of the population and are congenital in origin; up to 40% are associated with calculi. Type I diverticula are the most common and are closely related to minor calyces. Type II diverticula have a direct communication with the renal pelvis and tend to be larger and symptomatic. Caliceal diverticuli are usually asymptomatic, but patients may complain of flank pain or recurrent urinary tract infections. Frequently, many small calculi, rather than a solitary stone, are found in these obstructed cavities. When intervention was required in the past, treatment was with nephrectomy, heminephrectomy, or open surgical unroofing. Less invasive means are used today. Communications with the collecting system are commonly pinpoint and may be difficult to locate through a retrograde approach. Retrograde access into superior pole diverticula has been successful. Surprisingly, treatment may be successful with SWL if stone fragments are small enough to pass uneventfully. More commonly, percutaneous access and, more recently, laparoscopic means are used with success. Dilation of the caliceal neck, direct cauterization or sclerosis of the caliceal epithelium, or direct cauterization and sclerosis of the caliceal epithelium can help reduce stone recurrence rates.

Figure 17–12.



Source: McAninch JW, Lue TF: *Smith & Tanagho's General Urology*, 18th Edition: [www.accessmedicine.com](http://www.accessmedicine.com)

Copyright © The McGraw-Hill Companies, Inc. All rights reserved.

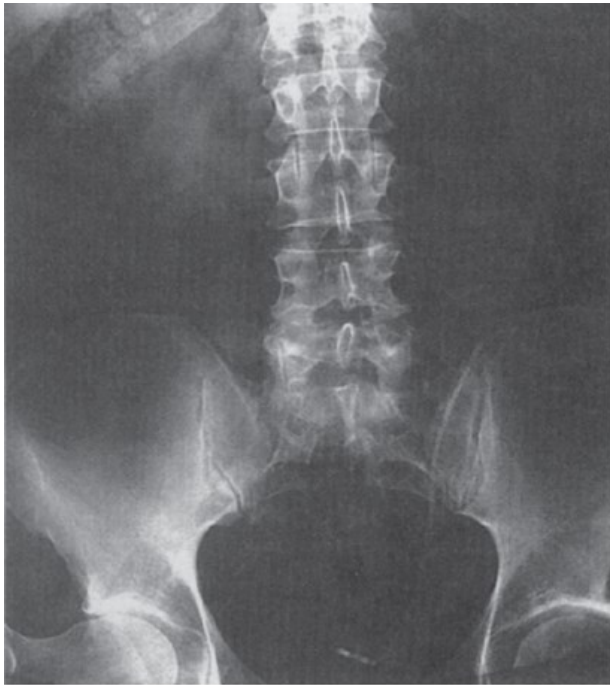Intravenous pyelogram demonstrating symptomatic right calyceal diverticula with numerous small calculi.



## Renal Malformations

Anatomic renal variants such as ectopic kidneys, including the horseshoe and pelvic kidney, predispose to renal calculi due to impaired urinary drainage. Pain symptoms appear to be no different from those reported in patients with normally positioned kidneys. Radiographic diagnosis may be difficult due to the unexpected location of the ureters and kidneys (Figure 17–13). If calculi can be targeted with SWL, most stone fragments pass surprisingly uneventfully. Large stone burdens should be approached percutaneously as in normally positioned kidneys. Severe outlet obstruction should be corrected with laparoscopic or open surgery, and concurrent calculi can be removed at the same setting. Aberrant vasculature should be appreciated before percutaneous, laparoscopic, and open procedures are undertaken.

Figure 17–13.



Source: McAninch JW, Lue TF: *Smith & Tanagho's General Urology*, 18th Edition: [www.accessmedicine.com](http://www.accessmedicine.com)

Copyright © The McGraw-Hill Companies, Inc. All rights reserved.

Scout abdominal radiograph demonstrating horseshoe kidney with lateral ureteral deviation and double-J ureteral stent. Extraosseous calcifications are left lower calyceal stones.

## Evaluation

### Differential Diagnosis

Urinary stones can mimic other retroperitoneal and peritoneal pathologic states. A full differential diagnosis of the acute abdomen should be made, including acute appendicitis, ectopic and unrecognized pregnancies, ovarian pathologic conditions including twisted ovarian cysts, diverticular disease, bowel obstruction, biliary stones with and without obstruction, peptic ulcer disease, acute renal artery embolism, and abdominal aortic aneurysm—to mention a few. Peritoneal signs should be sought during physical examination.

### History

A proper evaluation requires a thorough medical history. The nature of the pain should be evaluated, including its onset; character; potential radiation; activities that exacerbate or ease the pain; associated nausea, vomiting, or gross hematuria; and a history of similar pain. Patients with previous stones frequently have had similar types of pain in the past, but not always.

## Risk Factors

### Crystalluria

Crystalluria is a risk factor for stones. Stone formers, especially those with calcium oxalate stones, frequently excrete more calcium oxalate crystals, and those crystals are larger than normal ( $>12\ \mu\text{m}$ ). The rate of stone formation is proportional to the percentage of large crystals and crystal aggregates. Crystal production is determined by the saturation of each salt and the urinary concentration of inhibitors and promoters. Urine samples should be fresh; they should be centrifuged and examined immediately for optimum results. Cystine crystals are hexagonal; struvite stones appear as coffin lids; brushite ( $\text{CaHPO}_4$ ) stones are splinter like and may aggregate with a spoke-like center; calcium apatite— $(\text{Ca})_5(\text{PO}_4)_3(\text{OH})$ —and uric acid crystals appear as amorphous powder because the crystals are so small; calcium oxalate dihydrate stones are bipyramids; and calcium oxalate monohydrate stones are small biconcave ovals that may appear as a dumbbell. Cystine and struvite crystals are always abnormal and require further investigations. Other crystals are frequently found in normal urinalyses.

### Socioeconomic Factors

Renal stones are more common in affluent, industrialized countries. Immigrants from less industrialized nations gradually increase their stone incidence and eventually match that of the indigenous population. Use of soft water does not decrease the incidence of urinary stones.

### Diet

Diet may have a significant impact on the incidence of urinary stones. As per capita income increases, the average diet changes, with an increase in saturated and unsaturated fatty acids; an increase in animal protein and sugar; and a decrease in dietary fiber, vegetable protein, and unrefined carbohydrates. A less energy-dense diet may decrease the incidence of stones. This fact has been documented during war years when diets containing minimal fat and protein resulted in a decreased incidence of stones. Vegetarians may have a decreased incidence of urinary stones. High sodium intake is associated with increased urinary sodium, calcium, and pH and a decreased excretion of citrate; this increases the likelihood of calcium salt crystallization because the urinary saturation of monosodium urate and calcium phosphate (brushite) is increased. Fluid intake and urine output may have an effect on urinary stone disease. The average daily urinary output in stone formers is 1.6 L/d.

### Occupation

Occupation can have an impact on the incidence of urinary stones. Physicians and other white-collar workers have an increased incidence of stones compared with manual laborers. This finding may be related to differences in diet but also may be related to physical activity; physical activity may agitate urine and dislodge crystal aggregates. Individuals exposed to high temperatures may develop higher concentrations of solutes owing to dehydration, which may have an impact on the incidence of stones.

### Climate

Individuals living in hot climates are prone to dehydration, which results in an increased incidence of urinary stones, especially uric acid calculi. Although heat may cause a higher fluid intake, sweat loss results in lowered voided volumes. Hot climates usually expose people to more ultraviolet light, increasing vitamin D<sub>3</sub> production. Increased calcium and oxalate excretion has been correlated with increased exposure time to sunlight. This factor has more impact on light-skinned people and may help explain why African Americans in the United States have a decreased stone incidence. Global warming may increase the incidence of urinary stone disease.

### Family History

A family history of urinary stones is associated with an increased incidence of renal calculi. A patient with stones is twice as likely as a stone-free cohort to have at least one first-degree relative with renal stones (30% vs 15%). Those with a family history of stones have an increased incidence of multiple and early recurrences. Spouses of patients with calcium oxalate stones have an increased incidence of stones; this may be related to environmental or dietary factors. Large studies of identical twins have found that  $>50\%$  of stones have a significant genetic component. New evidence is finding a significant association between urinary stones and cardiovascular disease.

## Medications

A thorough history of medications taken may provide valuable insight into the cause of urinary calculi. The antihypertensive medication **triamterene** is found as a component of several medications, including Dyazide, and has been associated with urinary calculi with increasing frequency. Long-term use of antacids containing silica has been associated with the development of silicate stones. Carbonic anhydrase inhibitors may be associated with urinary stone disease (10–20% incidence). The long-term effect of sodium- and calcium-containing medications on the development of renal calculi is not known. Protease inhibitors in immunocompromised patients are associated with radiolucent calculi.

## Physical Examination

A detailed physical examination is an essential component of the evaluation of any patient suspected of having a urinary calculus. The patient presenting with acute renal colic typically is in severe pain, often attempting to find relief in multiple, frequently bizarre, positions. This fact helps differentiate patients with this condition from those with peritonitis, who are afraid to move. Systemic components of renal colic may be obvious, with tachycardia, sweating, and nausea often prominent. Costovertebral angle tenderness may be apparent. An abdominal mass may be palpable in patients with long-standing obstructive urinary calculi and severe hydronephrosis.

Fever, hypotension, and cutaneous vasodilation may be apparent in patients with urosepsis. In such instances, there is an urgent need for decompression of the obstructed urinary tract, massive intravenous fluid resuscitation, and intravenous antibiotics. Occasionally, intensive care support is needed.

A thorough abdominal examination should exclude other causes of abdominal pain. Abdominal tumors, abdominal aortic aneurysms, herniated lumbar disks, and pregnancy may mimic renal colic. Referred pain may be similar owing to common afferent neural pathways. Intestinal ileus may be associated with renal colic or other intraperitoneal or retroperitoneal processes. Bladder palpation should be performed because urinary retention may present with pain similar to renal colic. Incarcerated inguinal hernias, epididymitis, orchitis, and female pelvic pathologic states may mimic urinary stone disease. A rectal examination helps exclude other pathologic conditions.

## Radiologic Investigations

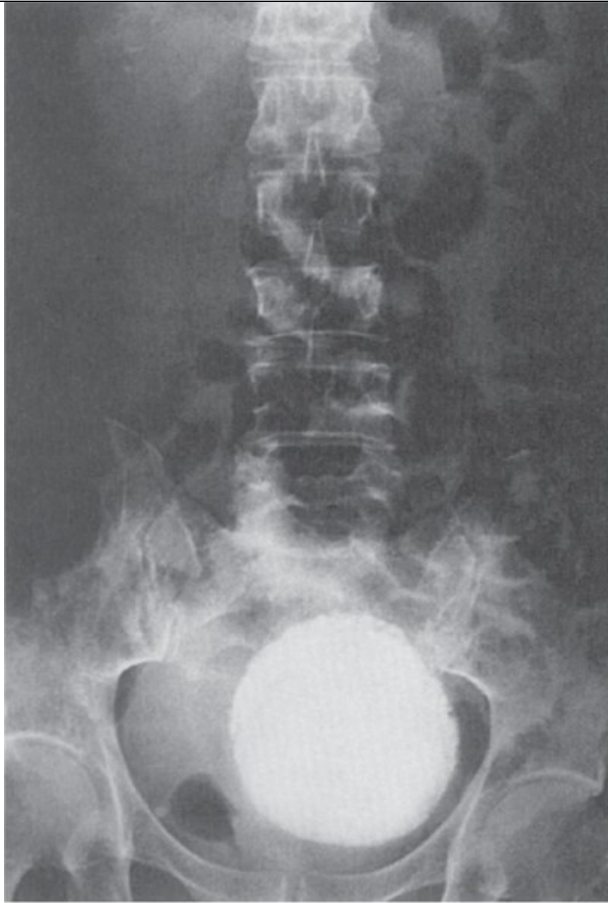
### Computed Tomography

Noncontrast spiral CT scans are now the imaging modality of choice in patients presenting with acute renal colic. It is rapid and is now less expensive than an intravenous pyelogram (IVP). It images other peritoneal and retroperitoneal structures and helps when the diagnosis is uncertain. It does not depend on an experienced radiologic technician to obtain appropriate oblique views when there is confusion with overlying bowel gas in a nonprepped abdomen. There is no need for intravenous contrast. Distal ureteral calculi can be confused with phleboliths. Prone positioning will help differentiate impacted ureterovesical junction calculi from stones that have already passed into the urinary bladder. Noncontrast images do not give anatomic details as seen on an IVP (eg, a bifid collecting system) that may be important in planning intervention. If intravenous contrast material is used during the study, a KUB film or three-dimensional reconstruction can give additional helpful information. Uric acid stones are visualized no differently from calcium oxalate stones. Matrix calculi have adequate amounts of calcium to be visualized easily by CT scan. HU can help predict stone type and hardness. Hard calcium oxalate monohydrate stones, for example, frequently have HU >1000, whereas uric acid stones frequently have HU <500. The increased use of CT scans has also increased the radiation exposure to stone patients, especially those with recurrent disease. CT scans should be used when the diagnosis is in doubt and should not be routinely utilized for diagnosis or surveillance.

### Intravenous Pyelography

An IVP can simultaneously document nephrolithiasis and upper-tract anatomy. It is rarely used today with the widespread availability of CT scan and ultrasound. Extraosseous calcifications on radiographs may be erroneously assumed to be urinary tract calculi (**Figure 17–14**). Oblique views easily differentiate gallstones from right renal calculi. Static hard-copy films can be interpreted by most clinicians. Anecdotally, small ureteral stones have passed spontaneously during such studies. An inadequate bowel preparation, associated ileus and swallowed air, and lack of available technicians may result in a less than ideal study when obtained during acute renal colic. A delayed, planned IVP may result in a superior study.

Figure 17–14.



Source: McAninch JW, Lue TF: *Smith & Tanagho's General Urology*, 18th Edition: [www.accessmedicine.com](http://www.accessmedicine.com)

Copyright © The McGraw-Hill Companies, Inc. All rights reserved.

Scout abdominal radiograph demonstrating large extraosseous calcification that represents a uterine fibroid. This easily could be confused with a large bladder calculus.

Acute forniceal rupture is not uncommonly associated with a highly obstructive ureteral calculus. It may result in dramatic radiographs but is of no clinical significance, and no specific intervention is required. The rupture may be precipitated by the osmotic diuresis of the intravenous contrast agent.

## Tomography

Renal tomography is useful to identify calculi in the kidney when oblique views are not helpful. It visualizes the kidney in a coronal plane at a set distance from the top of the x-ray table. Renal tomography may help identify poorly opacified calculi or stones difficult to appreciate secondary to overlying abdominal gas or morbid obesity when imaged with a traditional with a KUB.

## KUB Films and Directed Ultrasonography

A KUB film and renal ultrasound may be as effective as an IVP or CT scan in establishing a diagnosis. The ultrasound examination should be directed by notation of suspicious areas seen on a KUB film; it is, however, operator dependent. The distal ureter is easily visualized through the acoustic window of a full bladder. Edema and small calculi missed on an IVP can be appreciated with such studies. New studies comparing CT versus ultrasound for the acute diagnosis of urinary stones is underway.

## Retrograde Pyelography

Retrograde pyelography occasionally is required to delineate upper-tract anatomy and localize small or radiolucent offending calculi. Bulb

ureterograms frequently leak contrast material back into the bladder, resulting in a suboptimal study. Advancing an angiographic exchange catheter with or without the aid of a guidewire 3–4 cm into the ureter is an alternative technique. Intermittent fluoroscopic images direct appropriate injection volumes and help reduce the likelihood of pyelolymphatic, pyelosinus, and pyelovenous reflux.

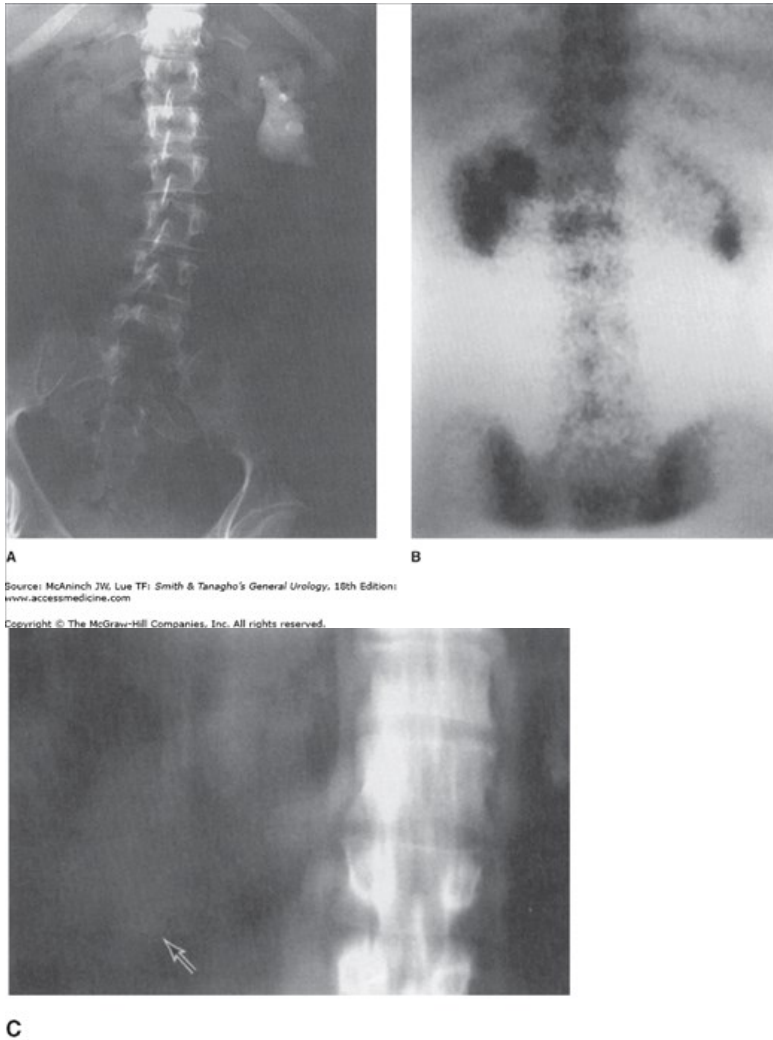
### Magnetic Resonance Imaging

Magnetic resonance imaging is a poor study to document urinary stone disease.

### Nuclear Scintigraphy

Nuclear scintigraphic imaging of stones has recently been appreciated. Bisphosphonate markers can identify even small calculi that are difficult to appreciate on a conventional KUB film (Figure 17–15). Differential radioactive uptake dependent on stone composition appreciated during in vitro studies cannot be appreciated on in vivo studies. Nuclear scintigraphy cannot delineate upper-tract anatomy in sufficient detail to help direct a therapeutic plan.

Figure 17–15.



Source: McAninch JW, Lue TF: *Smith & Tanagho's General Urology*, 18th Edition:  
www.accessmedicine.com

Copyright © The McGraw-Hill Companies, Inc. All rights reserved.

Source: McAninch JW, Lue TF: *Smith & Tanagho's General Urology*, 18th Edition:  
www.accessmedicine.com

Copyright © The McGraw-Hill Companies, Inc. All rights reserved.

**A:** Scout abdominal radiograph demonstrating large left staghorn renal calculus. **B:** Nuclear scintigraphic evaluation of renal calculi. Posterior view

demonstrating uptake on large left staghorn calculus after [furosemide](#) (Lasix) diuresis. Note right kidney with uptake in lower pole. **C:** Follow-up tomogram confirms calculus (*arrow*) in right lower pole missed on initial radiograph.

## Intervention

### Conservative Observation

Most ureteral calculi pass and do not require intervention. Spontaneous passage depends on stone size, shape, location, and associated ureteral edema (which is likely to depend on the length of time that a stone has not progressed). Ureteral calculi 4–5 mm in size have a 40–50% chance of spontaneous passage. In contrast, calculi >6 mm have a >15% chance of spontaneous passage. This does not mean that a 1-cm stone will not pass or that a 1- to 2-mm stone will always pass uneventfully.

Medical expulsive therapy (MET) helps facilitate spontaneous passage of ureteral stones. An alpha-blocker, nonsteroidal anti-inflammatory medications with or without low-dose steroids is now becoming standard care to optimize spontaneous ureteral stone passage. The vast majority of stones that pass do so within a 6-week period after the onset of symptoms. Ureteral calculi discovered in the distal ureter at the time of presentation have a 50% chance of spontaneous passage, in contrast to a 25% and 10% chance in the mid and proximal ureter, respectively.

### Dissolution Agents

The effectiveness of dissolution agents depends on stone surface area, stone type, volume of irrigant, and mode of delivery. Oral alkalinizing agents include sodium or potassium bicarbonate and potassium citrate. Extra care should be employed in patients susceptible to congestive heart failure or renal failure. Citrate is metabolized to bicarbonate and comes in a variety of preparations. Polycitra contains potassium and sodium citrate and citric acid. Bicitra contains only sodium citrate and citric acid. Food does not alter the effectiveness of these agents. Alternatively, orange juice alkalinizes urine. Intravenous alkalinization is effective with 1/6 molar sodium lactate.

Intrarenal alkalinization may be performed successfully under a low-pressure system (<25 cm water pressure). This may be achieved through a percutaneous nephrostomy tube or an externalized retrograde catheter. Agents include sodium bicarbonate, 2–4 ampules in 1 L of normal saline, producing a urinary pH between 7.5 and 9.0. Tromethamine-E and [tromethamine](#) can produce urinary pHs of 8.0–10.5 and are especially effective with pH-sensitive calculi as in uric acid and cystine lithiasis.

Cystine calculi can be dissolved with a variety of thiols, including d-penicillamine (0.5% solution), *N*-acetylcysteine (2–5% solution), and alpha-mercaptopropionylglycine (Thiola) (5% solution).

Struvite stone dissolution requires acidification and may be achieved successfully with Suby's G solution and hemiacidrin (Renacidin). Urinary pH may get down to 4.0. Hemiacidrin must be used with sterile urine, and careful monitoring of serum magnesium levels is required. The Food and Drug Administration has not approved hemiacidrin for upper-tract irrigations, and thus appropriate informed consent is required.

### Relief of Obstruction

Urinary stone disease may result in significant morbidity and possible mortality in the presence of obstruction, especially with concurrent infection. A patient with obstructive urinary calculi with fever and infected urine requires emergent drainage. Retrograde pyelography to define upper-tract anatomy is logically followed by retrograde placement of a double-J ureteral stent. On occasion, such catheters are unable to bypass the offending calculus or may perforate the ureter. In such situations, one must be prepared to place a percutaneous nephrostomy tube.

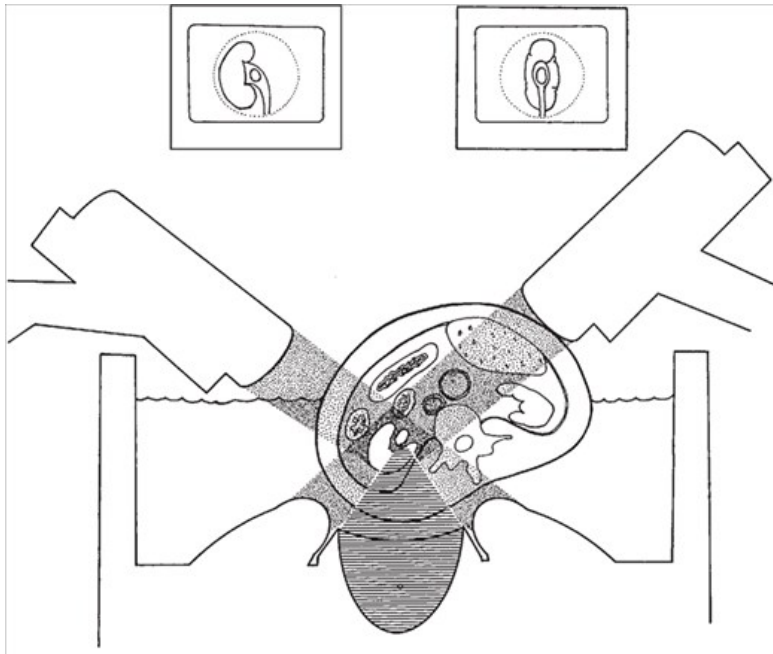
### Extracorporeal Shock Wave Lithotripsy

Extracorporeal SWL has revolutionized the treatment of urinary stones. The concept of using shock waves to fragment stones was noted in the 1950s in Russia. However, it was during the investigation of pitting on supersonic aircraft that Dornier, a German aircraft corporation, rediscovered that shock waves originating from passing debris in the atmosphere can crack something that is hard. It was the ingenious application of a model developed in hopes of understanding such shock waves that extracorporeal (outside the body) SWL emerged. The first clinical application with successful fragmentation of renal calculi was in 1980. The HM-1 (Human Model-1) lithotripter underwent modifications in 1982 leading to the HM-2 and, finally, to the widespread application of the HM-3 in 1983 ([Figure 17–16](#)). Since then, thousands of lithotriptors have been put into use around the world, with



millions of patients successfully treated.

Figure 17-16.



Source: McAninch JW, Lue TF: Smith & Tanagho's General Urology, 10th Edition: www.accessmedicine.com

Copyright © The McGraw-Hill Companies, Inc. All rights reserved.

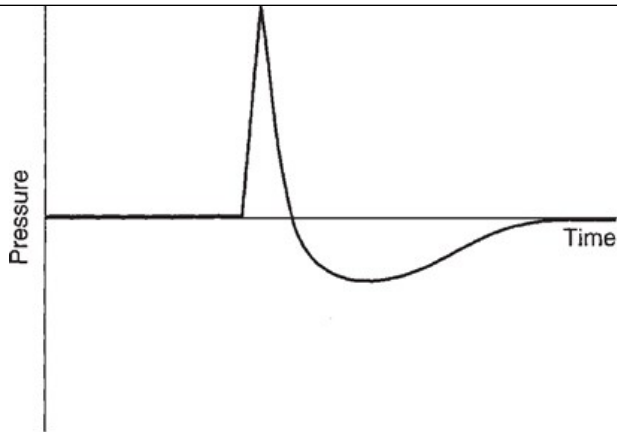
Diagrammatic representation of a Dornier HM-3 lithotripter.

All require an energy source to create the shock wave, a coupling mechanism to transfer the energy from outside to inside the body, and either fluoroscopic or ultrasonic modes, or both, to identify and position the calculi at a focus of converging shock waves. They differ in generated pain and anesthetic or anesthesiologist requirements, consumable components, size, mobility, cost, and durability. Focal peak pressures (400–1500 bar), focal dimensions (6 × 28 mm to 50 × 15 mm), modular design, varied distances (12–17.0 cm) between focus 1 (the shock wave source) and focus 2 (the target), and purchase price differentiate the various machines available today.

### Shock Wave Physics

In contrast to the familiar ultrasonic wave with sinusoidal characteristics and longitudinal mechanical properties, acoustic shock waves are not harmonic and have nonlinear pressure characteristics. There is a steep rise in pressure amplitude that results in compressive forces (Figure 17-17). There are two basic types of shock wave sources, supersonic and finite amplitude emitters.

Figure 17-17.



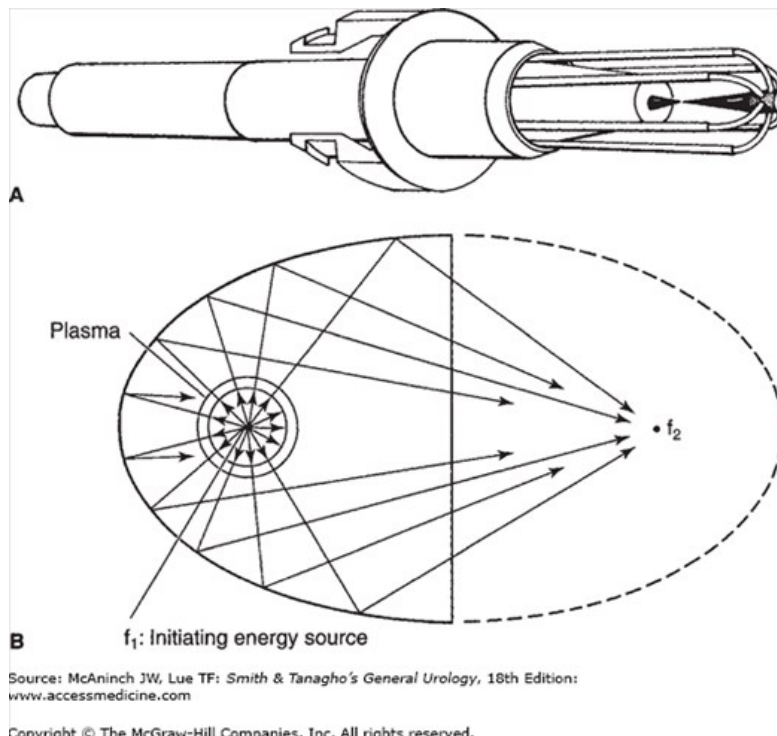
Source: McAninch JW, Lue TF: *Smith & Tanagho's General Urology*, 18th Edition: www.accessmedicine.com

Copyright © The McGraw-Hill Companies, Inc. All rights reserved.

Shock wave. Vertical axis represents pressure and horizontal axis represents time.

**Supersonic emitters** release energy in a confined space, thereby producing an expanding plasma and an acoustic shock wave. Such shock waves occur in nature—the familiar thunderstorm with lightning (an electrical discharge) followed by thunder (an acoustic sonic boom) is an analogous situation. Under controlled conditions, such an acoustic shock wave can successfully fragment calculi. The initial compression wave travels faster than the speed of sound in water and rapidly slows down to that speed. The traveling pressure wave is reduced in a nonlinear fashion. Medical applications have focused such waves to concentrate energy on a calculus (Figure 17-18).

Figure 17-18.



Source: McAninch JW, Lue TF: *Smith & Tanagho's General Urology*, 18th Edition: www.accessmedicine.com

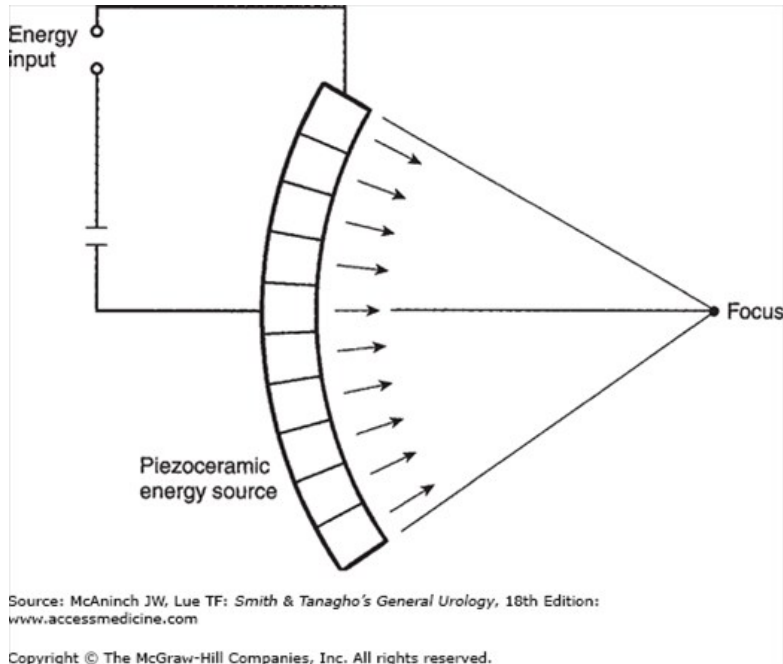
Copyright © The McGraw-Hill Companies, Inc. All rights reserved.

**A:** Supersonic shock wave emission from a spark gap electrode. **B:** Reflecting the shock wave from focus 1 to focus 2 allows for stone fragmentation.

**Finite amplitude emitters**, in contrast to point source energy systems, create pulsed acoustic shock waves by displacing a surface activated by electrical discharge. There are two major types of finite amplitude emitters, piezoceramic and electromagnetic. The piezoceramic variety results in a shock wave after an electrical discharge causes the ceramic component to elongate in such a manner that the surface is displaced and an acoustic

pulse is generated. Thousands of such components placed on the concave side of a spheric surface directed toward a focus result in high stress, strain, and cavitation pressures (Figure 17–19). Electromagnetic systems are similar in concept to a stereo speaker system. An electrical discharge to a slab, adjacent to an insulating foil, creates an electric current that repulses a metal membrane, displacing it and generating an acoustic pulse into an adjacent medium. These waves need to be focused toward the offending stone.

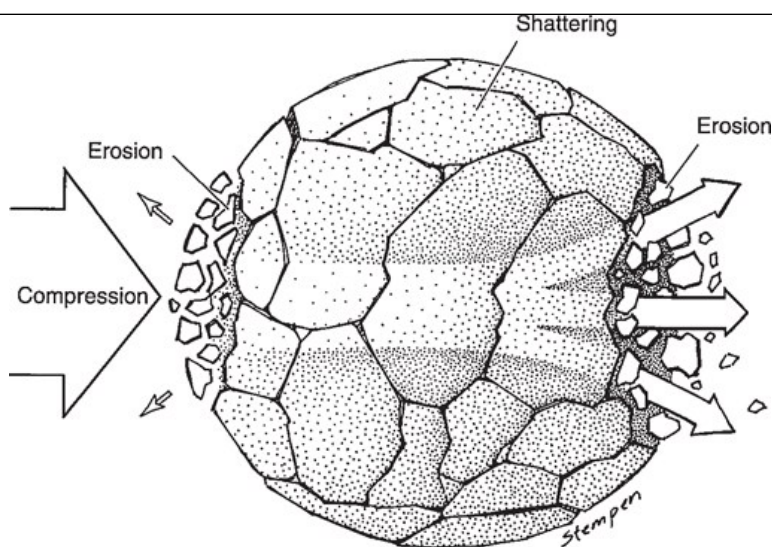
Figure 17–19.



Piezoceramic finite amplitude emitter. Ceramic components are placed on the concave surface of a sphere and each component is directed to an identified focus.

All shock waves, despite their source, are capable of fragmenting stones when focused. Fragmentation is achieved by erosion and shattering (Figure 17–20). Cavitational forces result in erosion at the entry and exit sites of the shock wave. Shattering results from energy absorption with stress, strain, and shear forces. Surrounding biologic tissues are resilient because they are neither brittle nor are the shock waves focused on them.

Figure 17–20.



Source: McAninch JW, Lue TF: *Smith & Tanagho's General Urology*, 18th Edition: www.accessmedicine.com

Copyright © The McGraw-Hill Companies, Inc. All rights reserved.

Incoming shock waves result in fragmentation from erosion and shattering.

## Preoperative Evaluation

Physical examination should be as thorough as in preparation for any other surgical procedure. Vital signs including blood pressure should be noted. Body habitus including any gross skeletal abnormalities, contractures, or excessive weight (>300 lb) may severely limit or preclude SWL. Borderline individuals require simulation before treatment. Pregnant women and patients with large abdominal aortic aneurysms or uncorrectable bleeding disorders should not be treated with SWL. Individuals with cardiac pacemakers should be thoroughly evaluated by a cardiologist. If SWL is contemplated, a cardiologist with thorough knowledge and with the ability to override the pacemaker should be present in the lithotripsy suite.

## Intraoperative Considerations

### Stone Localization

Proper patient positioning is a prerequisite for successful lithotripsy. Palpating the patient's ribs and pelvic bony girdle can approximate appropriate positioning. Anterior located kidneys, medial oriented portions of a horseshoe kidney, or transplant kidneys are best treated in the prone position. Understanding positioning options with the various lithotriptors available today is required to optimize therapy.

Small or poorly calcified calculi can be difficult to image with fluoroscopy, irrespective of their location. Placing a ureteral catheter identifies known anatomy and supplies an injection port for radiocontrast agents. A poorly calcified caliceal calculus can be identified by injecting dilute contrast agents into the collecting system and then focusing on the appropriate calyx or filling defect. In patients who cannot have retrograde stents placed, intravenous contrast agents may be used to help localize and thus focus on such stones.

### Fluoroscopic Imaging

The conditions for fluoroscopic imaging include appropriate collimation, dimmed room lighting, and adequate bowel preparation to decrease bothersome bowel gas and thus decrease radiation exposure and improve the quality of the fluoroscopic image. Intermittent fluoroscopy reveals movement of calculi with respiration and is helpful in locating and focusing on offending calculi.

### Ultrasonic Imaging

Ultrasound localization has the advantage of eliminating radiation exposure to the patient or lithotripsy team. There are two basic types: the coaxial unit, aligned with the shock wave generator, and the articulating arm unit with a mobile transducer. Ultrasound can easily identify radiolucent or small calculi that are difficult to visualize with fluoroscopy. However, ureteral or other medially located calculi may be difficult or impossible to identify,

especially in nonobstructive collecting systems. Visualization may be difficult or impossible with obese patients. Proficiency in ultrasound localization and assessment of fragmentation has a longer learning curve than that of fluoroscopy. Ultrasound images may be confusing when multiple stones or stone fragments are present.

### **Coupling**

Successful fragmentation requires effective coupling. Coupling devices should have properties similar to those of human skin. Optimal systems should prevent pain, ecchymoses, hematomas, or skin breakdown. Interfaces between gas and tissue can result in tissue damage. Air bubbles entrapped by hair, by bandages from prior percutaneous procedures, or by inadequately degassed fluid or air in coupling cushions can significantly impede directed shock waves and result in skin ecchymoses or breakdown. Despite adequate coupling, fragmentation may be inadequate owing to refraction and reflection of shock waves at tissue interfaces, especially with obese patients.

The water bath provides good coupling. Submersion of patients can result in profound hemodynamic changes including peripheral venous compression resulting in increased right atrial pressure, increased pulmonary capillary wedge pressure, and increased cardiac index. These hemodynamic changes should be appreciated and appropriate monitoring should be used in individuals with marginal cardiovascular reserve.

In contrast, water cushion coupling systems have decreased water demands. A coupling gel like those used with ultrasonography provides an excellent interface with skin. The volume of such water cushions can frequently be adjusted to help focus calculi when patients are either extremely thin (eg, children) or obese. Very small patients may require an interposed bag (1–3 L) of normal saline to help with coupling. Both water coupling systems require degassed water to decrease water bubbles.

### **Shock Wave Triggering**

Triggering shock waves with the electrocardiogram was originally performed to decrease cardiac dysrhythmias. The lithotripter would sense the large swing of the QRS complex and initiate the shock wave 20 ms later; this would decrease shock waves during the repolarization phase of the cardiac cycle (myocardium is most sensitive during this time). If cardiac dysrhythmias occur, interruption of the procedure frequently stops them. However, if they continue, standard medical therapy is effective. Conceptually, it makes more sense to trigger the shock waves in response to the respiratory cycle to optimize accurate focusing on the offending calculi that move with respiratory motion. Such systems are available. Most lithotriptors are now triggered without electrocardiogram gating and with unusual associated cardiac dysrhythmias. This can speed up therapy, especially in those with slow heart rates that are not amenable to pharmacologic manipulation. Slow rates of shock waves have shown increased stone fragmentation efficiency.

### **Fragmentation**

Safe shock wave dosage is unknown. Shock waves induce trauma, including intrarenal and perirenal hemorrhage and edema, and thus the minimal shocks needed to achieve fragmentation should be given. Casual overtreatment should be avoided since long-term complications are not yet known.

Determination of adequate fragmentation during treatment may be difficult. Initial sharp edges become fuzzy or blurred and have a shotgun-blast-like appearance. Stones that were initially visualized may disappear after successful fragmentation. Intermittent visualization ensures accurate focusing and assessment of progress and eventual termination of the procedure.

Bilateral nephrolithiasis may be treated in the same setting. One must first approach the side that is symptomatic or potentially more troublesome. If there is uncertainty concerning a large stone burden, one or more double-J catheters should be placed to decrease the likelihood of bilateral obstruction.

### **Postoperative Care**

Patients should be encouraged to maintain an active ambulatory status to facilitate stone passage. Gross hematuria should resolve during the first postoperative week. Fluid intake should be encouraged. Patients may return to work as soon as they feel comfortable in doing so.

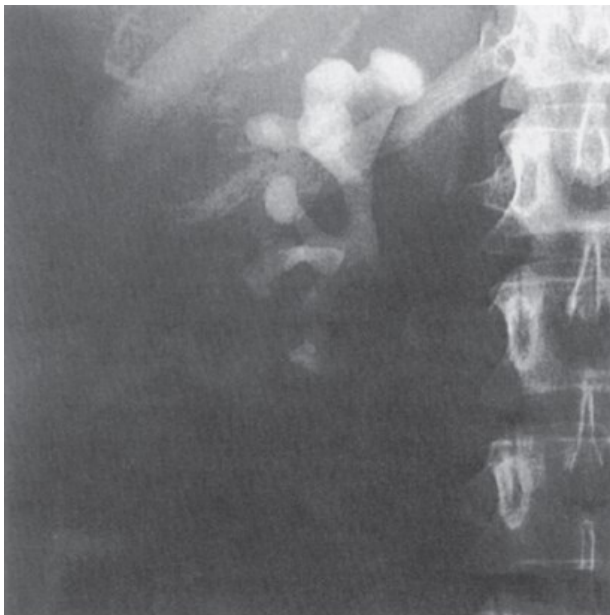
Abdominal pain may be related to the shock waves. Severe pain unresponsive to routine intravenous or oral medications should alert the physician for possible rare (0.66%) perirenal hematomas. In such a situation, CT scan should then be undertaken to stage the injury.

SWL is not associated with the development of hypertension. Stone burden correlates with postoperative complications. Steinstrasse (stone street) or

accumulation and back-up of stone gravel in a ureter can be frustrating. It should be specifically ruled out when postoperative radiographs are evaluated. Asymptomatic individuals can be followed up with serial KUBs and ultrasonography. Severe pain or fever requires intervention. Percutaneous nephrostomy drainage is usually uncomplicated owing to the associated hydronephrosis. Decompressing the collecting system allows for effective coaptation of the ureteral walls and encourages resolution of the problem. It is only in the rare patient that steinstrasse does not resolve with the procedures outlined; such cases require retrograde endoscopic manipulations to relieve the obstructed stone fragments. Usually, one finds one or two relatively large fragments that are obstructing. With their removal, the columnation of fragments resolves.

Patients with large renal pelvic calculi (1.5 cm) have a stone-free rate at 3 months approximating 75%, in comparison with those with a similar stone in a lower calyx, which approximates only 35%. Patients with small renal pelvic stones (<1.5 cm) have approximately a 90% stone-free rate in comparison with those with similar stones in a middle calyx (approximately 75%) or lower calyx (approximately 50%). Lower calyceal stone-free rates are increased with a small stone burden, a short and wide infundibulum, and a nonacute infundibulopelvic angle. Overall, approximately 75% of patients with renal calculi treated with SWL become stone free in 3 months. As stones increase in size, stone-free rates decrease, more so in the lower and middle calyces than in superior calyceal and renal pelvic locations (Figure 17–21).

Figure 17–21.



Source: McAninch JW, Lue TF: *Smith & Tanagho's General Urology*, 18th Edition: [www.accessmedicine.com](http://www.accessmedicine.com)

Copyright © The McGraw-Hill Companies, Inc. All rights reserved.

Plain abdominal radiograph demonstrating complete staghorn calculus with the renal pelvic extending into all infundibula and calyces.

## Ureteroscopic Stone Extraction

Ureteroscopic stone extraction is highly efficacious for lower ureteral calculi. The use of small-caliber ureteroscopes and the advent of balloon dilation or ureteral access sheaths have increased stone-free rates dramatically. Even relatively large-caliber endoscopes without balloon dilation are effective in lower ureteral stone retrieval. Stone-free rates approach 95–100% and are dependent on stone burden and location, length of time the stone has been impacted, history of retroperitoneal surgery, and the experience of the operator. Complication rates are rare; the rates increase when manipulations venture into the proximal ureter. Calculi that measure <6–8 mm are frequently removed intact. Nitinol baskets are less traumatic than older round or flat-wired stone baskets. Excessive force with any instrument in the ureter may result in ureteral injury.

A variety of lithotrites can be placed through an ureteroscope, including electrohydraulic, solid and hollow-core ultrasonic probes, a variety of laser systems, and pneumatic systems such as the Swiss lithoclast. Electrohydraulic lithotrites have power settings as high as 120 V that result in a cavitation bubble, followed by collapse of this bubble causing subsequent shock waves. Care should be taken to keep the tip of the electrode away from surrounding tissue and the tip of the endoscope. Ultrasonic lithotrites have a piezoceramic energy source that converts electrical energy into



ultrasonic waves in the range of 25,000 Hz. This vibratory action is effective in fragmenting calculi. Hollow probes can suction stone fragments and debris simultaneously. Laser systems (especially the Holmium) are discussed elsewhere in this book but are the most common lithotrite to fragment calculi. The electromechanical impactors are similar to jackhammers with a movable piston-like tip that fragments calculi.

## Percutaneous Nephrolithotomy

Percutaneous removal of renal and proximal ureteral calculi is the treatment of choice for large (>2.5 cm) calculi; those resistant to SWL; select lower pole calyceal stones with a narrow, long infundibulum and an acute infundibulopelvic angle; and instances with evidence of obstruction; the method can rapidly establish a stone-free status. Needle puncture is directed by fluoroscopy, ultrasound, or both, and is routinely placed from the posterior axillary line into a posterior inferior calyx. Superior caliceal puncture may be required, and in such situations, care should be taken to avoid injury to the pleura, lungs, spleen, and liver. Tract dilation is performed by sequential plastic dilators (Amplatz system), telescoping metal dilators (Alken), or balloon dilation. Tracts placed during open renal procedures are frequently tortuous and suboptimal for subsequent endourologic procedures.

Percutaneous extraction of calculi requires patience and perseverance. Residual calculi can be retrieved with the aid of flexible endoscopes, additional percutaneous puncture access, follow-up irrigations, SWL, or additional percutaneous sessions. Realistic goals should be established. Patients should be informed that complex calculi frequently require numerous procedures.

Maintenance of body temperature with appropriate blankets during preoperative patient positioning helps to prevent bleeding diatheses associated with hypothermia. Blood transfusion rates are typically <4–5%. Multiple percutaneous punctures are associated with a greater blood loss. Overall, such procedures are safe and effective.

## Open Stone Surgery

Open stone surgery is the historic way to remove calculi, yet it is rarely used today. The morbidity of the incision, the possibility of retained stone fragments, and the ease and success of less invasive techniques have made these procedures rare.

## Other Renal Procedures

Partial nephrectomy is appropriate with a large stone burden in a renal pole with marked parenchymal thinning. Caution should be taken with a simple nephrectomy even with a normal contralateral kidney, as stones are frequently associated with a systemic metabolic defect that may recur in the contralateral kidney. What may seem prudent and simple today may be regretted tomorrow.

Other unusual procedures include ileal ureter substitution performed with the hope of decreasing pain with frequent stone passage. Autotransplantation with pyelocystostomy is another option for patients with rare malignant stone disease.

## Ureterolithotomy

Long-standing ureteral calculi—those inaccessible with endoscopy and those resistant to SWL—can be extracted with an ureterolithotomy. Again, a preoperative radiograph documents stone location and directs an appropriate incision. The proximal ureter may be approached with a dorsal lumbotomy. An incision lateral to the sacrospinalis muscles allows medial retraction of the quadratus lumborum. The anterior fascicle of the dorsal lumbar fascia must be incised to gain proper exposure despite the appearance of potentially opening the peritoneum. Once the ureter is identified, a vessel loop or a Babcock clamp should be placed proximal to the stone to prevent frustrating stone migration. Extension of this incision is limited superiorly by the 12th rib and inferiorly by the iliac crest. A longitudinal incision over the stone with a hooked blade exposes the calculus. The nerve hook is excellent to help tease out the stone. A flank or anterior abdominal muscle splitting incision gives excellent exposure to mid and distal ureteral stones.

## Prevention

In general, 50% of patients experience recurrent urinary stones within 5 years without prophylactic intervention. Appropriate education and preventive measures are best instituted with a motivated patient after spontaneous stone passage or surgical stone removal. Risk factors as described previously should be identified and modified, if possible. Irrespective of the final metabolic evaluation and stone analysis, the patient's fluid intake should be about 1.5–2.0 L/24 hour. Fluids should be encouraged during mealtime. In addition, liquids should be increased approximately 2 hours after meals.

Water produced as a metabolic by-product reaches its nadir at this time, and thus the body is relatively dehydrated. Fluid ingestion also should be encouraged to force a nighttime diuresis adequate to awaken the patient to void. Awakening and ambulating to void limits urinary stasis and offers an opportunity to ingest additional fluids. These lifestyle changes are difficult to maintain and should be encouraged during subsequent office visits. Motivated patients who regularly return to a urinary stone clinic have a reduced stone recurrence rate that is probably due to increased compliance.

## Metabolic Evaluation

A systematic metabolic evaluation should be instituted after a patient has recovered from urinary stone intervention or spontaneous stone passage. Stone analysis should be obtained to help direct the workup. An outpatient urine collection during typical activities and fluid intake helps unmask significant abnormalities. An initial 24-hour urine collection for calcium stone formers should include tests for calcium, uric acid, oxalate, citrate, phosphate, sulfate, sodium, volume, and pH. An open dialog with local laboratories helps to standardize collection routines and determine whether an outside laboratory is preferred. Baseline serum levels for blood urea nitrogen, creatinine, calcium (with or without parathyroid hormone), phosphorous, and uric acid are appropriate. Twenty-four-hour urine values help to direct appropriate prophylactic therapy.

## Oral Medications

### Alkalinizing pH Agents

Potassium citrate is an oral agent that elevates urinary pH effectively by 0.7–0.8 pH units. Typical dosing is 60 mEq in three or four divided doses daily. It is available in wax matrix 10- or 15-mEq tablets, liquid preparations, and crystals that must be mixed with fluids. The effect is maintained over many years. Care should be taken in patients susceptible to hyperkalemia, those with renal failure, and those taking potassium-sparing diuretics. Although the medication is usually well tolerated, some patients may complain of abdominal discomfort, especially with tablet preparations. It is indicated in those with calcium oxalate calculi secondary to hypocitraturia (<450 mg/d), including those with renal tubular acidosis. Potassium citrate also may be used effectively to treat uric acid lithiasis and nonsevere forms of hyperuricosuric calcium nephrolithiasis. There are no effective long-term urinary acidifying agents.

### Gastrointestinal Absorption Inhibitor

**Cellulose** phosphate binds calcium in the gut and thereby inhibits calcium absorption and urinary excretion and is appropriate for patients with type 1 absorptive hypercalciuria. Patients should have normal parathyroid hormone and serum calcium and phosphate values, no evidence of bone disease, and evidence of increased intestinal calcium absorption. The drug decreases the urinary saturation of calcium phosphate and calcium oxalate. It may increase urinary oxalate and urinary phosphate levels. A typical starting dosage is 5 g three times daily with meals; the dosage may be titrated by following 24-hour urinary calcium levels. Urinary magnesium, calcium, oxalate, and sodium levels and serum parathyroid hormone should be monitored one to two times yearly. Magnesium supplements are frequently required and should be taken at least 1 hour before or after **cellulose** phosphate is taken. **Cellulose** phosphate is associated with a sodium load and should be used with caution in those with congestive heart failure. Gastrointestinal side effects are infrequent; they include dyspepsia and loose bowel movements.

**Cellulose** phosphate may be suboptimal treatment for postmenopausal women who are at risk for bone disease. An alternative treatment for such patients would be hydrochlorothiazides supplemented with potassium citrate to offset the potential hypokalemia and hypocitraturia.

### Phosphate Supplementation

Renal phosphate leak is best treated by replacing phosphate. Phosphate absorption may be inhibited in the presence of aluminum-, magnesium-, or calcium-containing antacids. This treatment should be used with caution in digitalized patients and in those with severe renal failure, Addison's disease, or severe hepatic dysfunction. It is generally well tolerated. Dosing can begin with 250 mg three to four times daily and may be doubled depending on follow-up serum electrolyte, calcium, and phosphorus levels.

### Diuretics

Thiazides can correct the renal calcium leak associated with renal hypercalciuria. This prevents a secondary hyperparathyroid state and its associated elevated vitamin D synthesis and intestinal calcium absorption. A rapid decrease in urinary calcium excretion is appreciated and is sustained long term (>10 years). A starting dose of 25 mg may be titrated based on urinary calcium levels. Side effects are usually well tolerated. Potassium levels should be

monitored. Hypokalemia induces a hypocitraturic state; potassium replacement corrects the hypokalemia and its associated hypocitraturia.

Thiazides result in a transient decrease in urinary calcium excretion in absorptive hypercalciurics. Urinary calcium excretion rebounds to pretreatment values in 50% of such patients after 4–5 years of therapy. Dietary changes are not believed to be responsible for this phenomenon. Thiazides do not restore normal intestinal absorption of calcium.

### Calcium Supplementation

Enteric hyperoxaluric calcium nephrolithiasis is effectively treated with calcium supplements. Calcium gluconate and calcium citrate are better absorbed and are more effective in increasing serum calcium availability than are other forms of calcium. Calcium carbonate, calcium phosphate, and oyster shell are forms of calcium that are less efficiently absorbed; they remain in the intestinal lumen, available to bind oxalate, thus reducing its absorption. These less efficiently absorbed forms of calcium are optimal to treat enteric hyperoxaluric calcium nephrolithiasis and must be given with meals to be effective.

### Uric Acid-Lowering Medications

[Allopurinol](#) is used to treat hyperuricosuric calcium nephrolithiasis with or without hyperuricemia. Unlike uricosuric agents that reduce serum uric acid levels by increasing urinary uric acid excretion, [allopurinol](#) is a xanthine-oxidase inhibitor and reduces both serum and urinary levels of uric acid. It has no impact on the biosynthesis of purines; rather, it acts exclusively on purine catabolism. Elevated levels of xanthine and hypoxanthine in the urine secondary to [allopurinol](#) have not been associated with nephrolithiasis. [Allopurinol](#) is a potentially dangerous drug and should be discontinued at the first appearance of a skin rash, which infrequently may be fatal. Therapy can start at 300 mg/day. It is tolerated best when taken after meals.

### Urease Inhibitor

Acetohydroxamic acid is an effective adjunctive treatment in those with chronic urea-splitting urinary tract infections associated with struvite stones. Acetohydroxamic acid reversibly inhibits bacterial urease, decreasing urinary ammonia levels, and will subsequently acidify urine. It is best used as prophylaxis after removal of struvite stones. It also may be used after unsuccessful attempts at curative surgical removal of calculi or culture-specific antibiotic therapy. Patients with serum creatinine >2.5 mg/dL are unable to achieve therapeutic urinary levels. Acetohydroxamic acid is not effective with nonurease-producing bacteria. Long-term data (>7 years) are unavailable. A significant number of patients complain of side effects, including headaches that are usually short lived and responsive to [aspirin](#) compounds. Other frequent complaints include nausea, vomiting, anorexia, nervousness, and depression. A typical dosing regimen is one 250-mg tablet three or four times daily (total dosage: 10–15 mg/kg/d).

### Prevention of Cystine Calculi

Conservative measures, including massive fluid intake and urinary alkalinization, are frequently inadequate to control cystine stone formation. [Penicillamine](#), the same drug that is used to chelate excess [copper](#) in the treatment of Wilson's disease, undergoes a thiol–disulfide exchange with cystine. This reduces the amount of urinary cystine that is relatively insoluble. Cystine solubility is pH dependent (pH 5.0: 150–300 mg/L; pH 7.0: 200–400 mg/L; pH 7.5: 220–500 mg/L). *d*-Penicillamine is associated with numerous and frequent side effects, including rashes and hematologic, renal, and hepatic abnormalities. An initial dosage of 250 mg daily in three to four divided doses may help reduce severe side effects. It may be increased gradually to 2 g/d. Dosage should be titrated with quantitative urinary cystine values. [Penicillamine](#) increases the requirement of [pyridoxine](#) (vitamin B6), which should be supplemented with 25–50 mg/d.

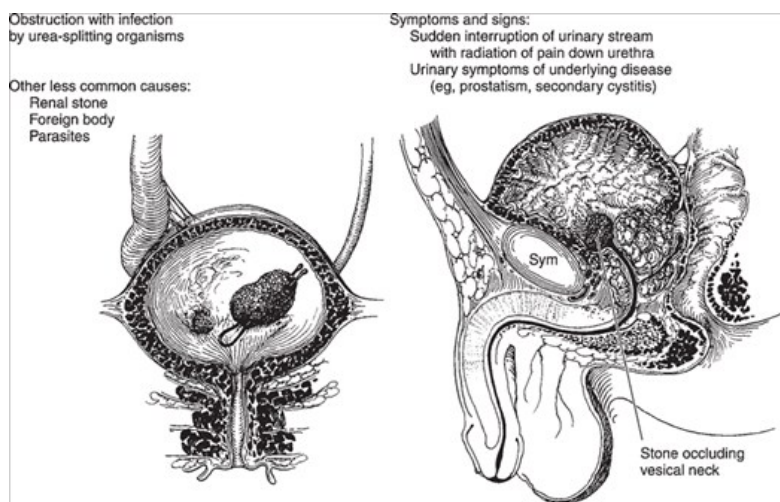
Mercaptopropionylglycine (Thiola) is better tolerated by patients than is [penicillamine](#). Mercaptopropionylglycine, a reducing agent, binds to the sulfide portion of cystine, forming a mixed disulfide (Thiola–cysteine) water-soluble compound. It may retard the rate of new stone formation. The dosage should be titrated with repeat 24-hour urinary cystine values. An initial dosage may be 200–300 mg three times daily, either 1 hour before or 2 hours after each meal. Side effects are not infrequent and may include drug fever; nausea, vomiting, and gastrointestinal upset; rash, wrinkling, or friable skin; lupus-like symptoms, decreased taste perception; and a variety of hematologic disorders.

## Bladder Stones

Bladder calculi usually are a manifestation of an underlying pathologic condition, including voiding dysfunction or a foreign body. Voiding dysfunction

may be due to a urethral stricture, benign prostatic hyperplasia, bladder neck contracture, or flaccid or spastic neurogenic bladder, all of which result in static urine. Foreign bodies such as Foley catheters and forgotten double-J ureteral catheters can serve as nidi for stones (Figure 17-22). Most bladder calculi are seen in men. In developing countries, they are frequently found in prepubescent boys. Stone analysis frequently reveals ammonium urate, uric acid, or calcium oxalate stones. Bladder stones can be solitary or numerous (Figure 17-23). Patients present with irritative voiding symptoms, intermittent urinary stream, urinary tract infections, hematuria, or pelvic pain. Physical examination is unrevealing. A large percentage of bladder stones are radiolucent (uric acid). Ultrasound of the bladder identifies the stone with its characteristic postacoustic shadowing. The stone moves with changing body position.

Figure 17-22.

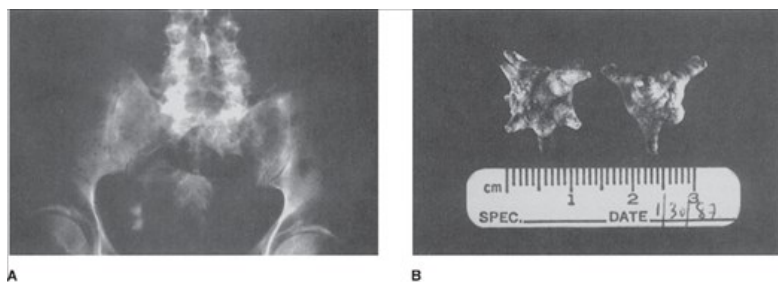


Source: McAninch JW, Lue TF: Smith & Tanagho's General Urology, 10th Edition: www.accessmedicine.com

Copyright © The McGraw-Hill Companies, Inc. All rights reserved.

Genesis and symptoms and signs of vesical calculus.

Figure 17-23.



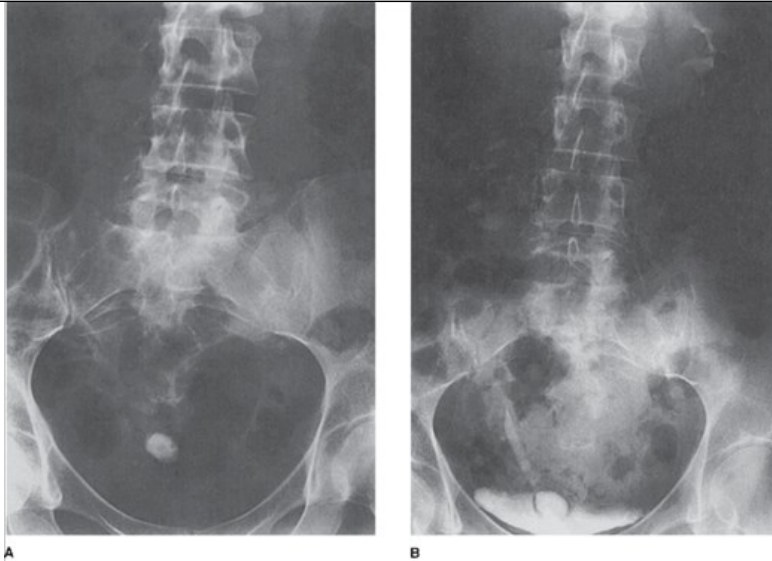
Source: McAninch JW, Lue TF: Smith & Tanagho's General Urology, 10th Edition: www.accessmedicine.com

Copyright © The McGraw-Hill Companies, Inc. All rights reserved.

**A:** Plain abdominal radiograph demonstrating two bladder calculi. **B:** Gross picture of removed bladder calculi. Note the characteristic shape of jackstones typically composed of uric acid.

Stones within a ureterocele do not move with body position (Figure 17-24) as seen on ultrasound examination. They frequently are nonobstructive. Endoscopic incision and stone removal rarely results in vesicoureteral reflux. The mode of stone removal for other bladder stones should be directed by the underlying cause.

Figure 17-24.



Source: McAninch JW, Lue TF: Smith & Tanagho's General Urology, 18th Edition:  
www.accessmedicine.com

Copyright © The McGraw-Hill Companies, Inc. All rights reserved.

**A:** Scout abdominal radiograph demonstrating extraosseous calcification in the region of the bladder. **B:** Intravenous pyelogram demonstrates stone to be within a ureterocele.

Early instruments used to remove bladder calculi were both clever and bizarre. Simple mechanical crushing devices are still used today. Mechanical lithotrites should be used with caution to prevent bladder injury when the jaws are closed. Ensuring a partially full bladder and endoscopic visualization of unrestricted lateral movement before forceful crushing of the stones helps reduce this troublesome complication. Cystolitholapaxy allows most stones to be broken and subsequently removed through a cystoscope. Electrohydraulic, ultrasonic, laser, and pneumatic lithotrites similar to those used through a nephroscope are effective. Cystolithotomy can be performed through a small abdominal incision.

## Prostatic and Seminal Vesicle Stones

Prostatic calculi are found within the prostate gland per se and are found uncommonly within the prostatic urethra. They are thought to represent calcified corpora amylacea and are rarely found in boys. Usually small and numerous, they are noted to be tannish gray in color during transurethral resection of the prostate. They are commonly located at the margin of the surgically resected adenoma and are composed of calcium phosphate. Although usually of no clinical significance, rarely they are associated with chronic prostatitis. Large prostatic calculi may be misinterpreted as a carcinoma. The prostate is usually mobile, however, and a radiograph or transrectal ultrasound helps to confirm the diagnosis.

Seminal vesicle stones are smooth and hard and are extremely rare. They may be associated with hematospermia. Physical examination reveals a stony hard gland, and when multiple stones are present, a crunching sensation may be noted. These stones occasionally are confused with tuberculosis of the seminal vesicle.

## Urethral and Preputial Stones

Urethral calculi usually originate from the bladder and rarely from the upper tracts. Most ureteral stones that pass spontaneously into the bladder can pass through the urethra unimpeded. Urethral stones may develop secondary to urinary stasis, secondary to a urethral diverticulum, near urethral strictures, or at sites of previous surgery. Most urethral stones in men present in the prostatic or bulbar regions and are solitary. Patients with recurrent pendulous urethral calculi without evidence of other pathologic conditions should be suspected of self-introduction of such stones in an attempt to obtain pain medications or for attention, as seen in Munchausen syndrome.

Females rarely develop urethral calculi owing to their short urethra and a lower incidence of bladder calculi. Most urethral stones found in women are associated with urethral diverticula.

Symptoms are similar to bladder calculi—intermittent urinary stream, terminal hematuria, and infection. The stones may present with dribbling or

during acute urinary retention. Pain may be severe and, in men, may radiate to the tip of the penis. The diagnosis may be confirmed by palpation, endoscopic visualization, or radiographic study.

Treatment should be directed by the underlying cause. Stones associated with a dense urethral stricture or complex diverticula can be removed during definitive open surgical repair. Small stones may be grasped successfully and removed intact. More frequently, they need to be fragmented and removed. Long-standing, large impacted stones are best removed through a urethrotomy.

Preputial calculi are rare and usually occur in adults. They develop secondary to a severe obstructive phimosis. They may occur secondary to poor hygiene with inspissated smegma. Diagnosis is confirmed by palpation. Treating the underlying cause with a dorsal preputial slit or a formal circumcision prevents recurrent calculi.

## Bibliography

### Urinary Ions

Milosevic D et al: Determination of urine saturation with computer program EQUIL 2 as a method for estimation of the risk of urolithiasis. J Chem Inf Comput Sci 1998;38:646. [PubMed: 9691474]

Moe OW, Bonny O: Genetic hypercalciuria. J Am Soc Nephrol 2005;16:729. [PubMed: 15689405]

Traxer O et al: Effect of ascorbic acid consumption on urinary stone risk factors. J Urol 2003;170(2, Pt 1):397–401.

Wallace RB et al: Urinary tract stone occurrence in the Women's Health Initiative (WHI) randomized clinical trial of calcium and vitamin D supplements. Am J Clin Nutr 2011;94(1):270–277. [PubMed: 21525191]

Knight J et al: Metabolism of fructose to oxalate and glycolate. Horm Metab Res 2010;42(12):868–873. [PubMed: 20842614]

Thurgood LA et al: Comparison of the specific incorporation of intracrystalline proteins into urinary calcium oxalate monohydrate and dihydrate crystals. J Proteome Res 2010;9(9):4745–4757. [PubMed: 20672853]

Tiselius HG: Standardized estimate of the ion activity product of calcium oxalate in urine from renal stone formers. Eur Urol 1989;16:48. [PubMed: 2714318]

Maalouf NM: Metabolic syndrome and the genesis of uric acid stones. J Ren Nutr 2011;21(1):128–131. [PubMed: 21195936]

Marangella M: Uric acid elimination in the urine. Pathophysiological implications. Contrib Nephrol 2005;147:132. [PubMed: 15604613]

Stoller ML: Gout and stones or stones and gout? J Urol 1995;154:1670. [PubMed: 7563317]

Pietrow PK et al: Durability of the medical management of cystinuria. J Urol 2003;169:68. [PubMed: 12478105]

Purohit RS, Stoller ML: Stone clustering of patients with cystine urinary stone formation. Urology 2004;63:630. [PubMed: 15072865]

Shekarritz B, Stoller ML: Cystinuria and other noncalcareous calculi. Endocrinol Metab Clin North Am 2002;31:951. [PubMed: 12474640]

Gargah T et al: Xanthine urolithiasis. Saudi J Kidney Dis Transpl 2010;21(2):328–331. [PubMed: 20228523]



Daudon M, Jungers P: Drug-induced renal calculi: Epidemiology, prevention and management. *Drugs* 2004;64(3):245–275. [PubMed: 14871169]

Shah HN et al: The management of renal matrix calculi: A single-centre experience over 5 years. *BJU Int* 2009;103(6):810–814. [PubMed: 18782302]

## Urinary Stone Inhibitors

Seltzer MA et al: Dietary manipulation with lemonade to treat hypocitraturic calcium nephrolithiasis. *J Urol* 1996;156:907. [PubMed: 8709360]

Shah O et al: Genetic and dietary factors in urinary citrate excretion. *J Endourol* 2005;19:177. [PubMed: 15798414]

Spivacow FR et al: Long-term treatment of renal lithiasis with potassium citrate. *Urology* 2010;76(6):1346–1349. [PubMed: 20399488]

Selvam R, Kalaiselvi P: Oxalate binding proteins in calcium oxalate nephrolithiasis. *Urol Res* 2003;31:242. [PubMed: 12856168]

Schwartz BF et al: Rethinking the role of urinary magnesium in calcium urolithiasis. *J Endourol* 2001;15:233. [PubMed: 11339386]

Evan AP et al: Renal histopathology of stone-forming patients with distal renal tubular acidosis. *Kidney Int* 2007;71(8):795–801. [PubMed: 17264873]

Meschi T et al: Body weight, diet and water intake in preventing stone disease. *Urol Int* 2004;72(Suppl 1):29–33.

## Urinary Stone Disease in Uncommon Situations

Ramsey S, McIlhenny C: Evidence-based management of upper tract urolithiasis in the spinal cord-injured patient. *Spinal Cord* 2011;49(9):948–954. [PubMed: 21625238]

Rosenberg E et al: Nephrolithiasis during pregnancy: Characteristics, complications, and pregnancy outcome. *World J Urol* 2011;29(6): 743–747. [PubMed: 21691721]

Lu HF et al: Donor-gifted allograft urolithiasis: Early percutaneous management. *Urology* 2002;59:25. [PubMed: 11796274]

Nowfar S et al: The relationship of obesity and gender prevalence changes in United States inpatient nephrolithiasis. *Urology* 2011;78(5):1029–1033. [PubMed: 21676441]

Taylor EN et al: Obesity, weight gain, and the risk of kidney stones. *JAMA* 2005;293:455. [PubMed: 15671430]

Baskin LS et al: The horseshoe kidney: Therapeutic considerations with urolithiasis. *J Endourol* 1989;3:51.

Ganpule AP, Desai MR: Urolithiasis in kidneys with abnormal lie, rotation or form. *Curr Opin Urol* 2011;21(2):145–153. [PubMed: 21285720]

Goumas-Kartalas I, Montanari E: Percutaneous nephrolithotomy in patients with spinal deformities. *J Endourol* 2010;24(7):1081–1089. [PubMed: 20399488]

20624080]

Gürgöze MK, Sarı MY: Results of medical treatment and metabolic risk factors in children with urolithiasis. *Pediatr Nephrol* 2011;26(6):933–937. [PubMed: 21113354]

Gross AJ, Herrmann TR: Management of stones in calyceal diverticulum. *Curr Opin Urol* 2007;17(2):136–140. [PubMed: 17285025]

Paonessa J et al: Squamous cell carcinoma of the renal pelvis associated with kidney stones: A case report. *Med Oncol* 2010;28(Suppl 1): S392–S394.

Berger AD et al: Patients with primary hyperparathyroidism—Why do some form stones? *J Urol* 2009;181(5):2141–2145. [PubMed: 19296981]

Johri N et al: An update and practical guide to renal stone management. *Nephron Clin Pract* 2010;116(3):c159–c171.

Kenny JE, Goldfarb DS: Update on the pathophysiology and management of uric acid renal stones. *Curr Rheumatol Rep* 2010; 12(2):125–129. [PubMed: 20425021]

Pak CY et al: Adequacy of a single stone risk analysis in the medical evaluation of urolithiasis. *J Urol* 2001;165:378–381. [PubMed: 11176377]

Albala DM et al: Lower pole I: A prospective randomized trial of extracorporeal shock wave lithotripsy and percutaneous nephrostolithotomy for lower pole nephrolithiasis—Initial results. *J Urol* 2001;166:2072–2080. [PubMed: 11696709]

Al-Kohlany KM et al: Treatment of complete staghorn stones: A prospective randomized comparison of open surgery versus percutaneous nephrolithotomy. *J Urol* 2005;173:469. [PubMed: 15643212]

Chaussy CG et al: First clinical experience with extracorporeally induced destruction of kidney stones by shock waves. *J Urol* 1982;127:417. [PubMed: 6977650]

Drach GW et al: Report of the United States co-operative study of extracorporeal shock wave lithotripsy. *J Urol* 1986;135:1127. [PubMed: 3520014]

Elbahnasy AM et al: Lower caliceal stone clearance after shock wave lithotripsy or ureteroscopy: The impact of lower pole radiographic anatomy. *J Urol* 1998;159:676. [PubMed: 9474124]

Lingeman JE et al: Blood pressure changes following extracorporeal shock wave lithotripsy and other forms of treatment for nephrolithiasis. *JAMA* 1990;263:1789. [PubMed: 2313851]

Akman T et al: Factors affecting bleeding during percutaneous nephrolithotomy: Single surgeon experience. *J Endourol* 2011;25(2): 327–333. [PubMed: 21214412]

Cracco CM et al: New developments in percutaneous techniques for simple and complex branched renal stones. *Curr Opin Urol* 2011;21(2):154–160. [PubMed: 21252683]

Irby PB et al: Percutaneous access techniques in renal surgery. *Tech Urol* 1999;5:29. [PubMed: 10374792]

Bagley DH: Removal of upper urinary tract calculi with flexible ureteropyeloscopy. *Urology* 1990;35:412. [PubMed: 2336771]

---

Herrera-Gonzalez G et al: Effectiveness of single flexible ureteroscopy for multiple renal calculi. J Endourol 2011;25(3):431–435. [\[PubMed: 21401396\]](#)

---